

## Case Report

# Management of Extensive Surgical Wounds of the Extremity after Tumour Resections Using Two Simultaneous Composite Flaps: Two Case Reports

Faizal A<sup>1</sup>, Ahmad SH<sup>2</sup>, Zulmi W<sup>3</sup>

<sup>1</sup>Plastic Surgical Unit, Department of Surgery, Faculty of Medicine, Universiti Kebangsaan Malaysia Medical Center, Kuala Lumpur, Malaysia.

<sup>2</sup>Reconstructive Sciences Unit, Department of Surgery, Faculty of Medicine, Universiti Kebangsaan Malaysia Medical Center, Kuala Lumpur, Malaysia.

<sup>3</sup>Department of Orthopaedics, School of Medical Sciences, Universiti Sains Malaysia, Kubang Kerian, Kelantan.

## Abstract

Tumour surgery for locally extensive malignant neoplasms of the extremity will sometimes result in extensive composite soft tissue defect. Local flaps are usually inadequate to cover these large defects. More than one tissue flap might be required to cover any exposed neurovascular structures, bone or prosthesis. We present two cases where two composite flaps were simultaneously used to cover extensive surgical defects after ablative tumour resections in the extremity. These resulted in uncomplicated wound healing and limb salvage.

**Key Words :** Limb salvage, double flap, extremity, tumours, extensive resection.

## Correspondence:

Dr Faizal Ali, Consultant Plastic Surgeon, Plastic Surgery Unit, Department of Surgery, Jalan Yaacob Latif, Bandar Tun Razak, 56000 Cheras, Kuala Lumpur, Malaysia. Tel: +603-91456202 Fax: +603-91737831 Email: [faizalali71@yahoo.co.uk](mailto:faizalali71@yahoo.co.uk)

Received: Jan 11 2011 Accepted: Mar 31 2011

## Introduction

The standard management for locally extensive malignant neoplasms involving the extremity in many developing countries is still amputation and the use of prosthesis. With the advent of multimodality therapy and microvascular tissue transfer, the trend is now moving towards limb salvage without compromising on the resection margins (1). Recurrence rate and overall survival after treatment with limb saving surgery are now similar to those after amputation (2)]. Ablative tumour surgery may sometimes result in an extensive composite tissue defect, especially if more than one compartment is involved. Soft tissue coverage in the form of tissue flap is required to cover the transplanted allograft or prosthesis, any exposed neurovascular structures and bone devoid of periosteum, which cannot be covered by local tissues. The complex composite defect (bone, soft

tissue and skin) presents a unique challenge to the reconstructive surgeon. Problems with adequate coverage, ease of insertion or the variety of tissues that need to be replaced are factors that need to be taken into account when planning the reconstructive options. More than one flap might be needed to satisfy all the above requirements.

## Case report 1

A 21-year-old gentleman presented with recurrent Grade 2 Giant cell tumour of the left distal femur. He had undergone curettage, bone grafting and cementing of his femur one year earlier. Wide en bloc resection of the tumour from the knee joint to 13 cm of bone proximally with most of the overlying muscle was performed. The resulting defect was a 20×8cm skin defect, 18cm bony defect with overlying soft tissue defect. A composite bilateral free osteoseptocutaneous fibula flap was

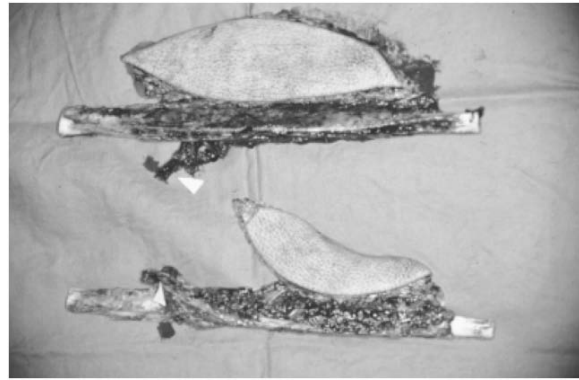
harvested ( Fig.1). The right harvested fibula measured 23 cm along with 20×7 cm of skin flap. The left harvested fibula measured 25 cm with overlying 14×5 cm of skin flap. The fibula was used as a double barrel strut to bridge the bony defect. They were held in place with plates and screws. The peroneal artery from both fibulas was anastomosed end to side to the popliteal artery, the peroneal vein from one fibula flap was anastomosed to one of the popliteal committante vein and the other peroneal vein to the committante vein of the sural vessel draining the gastrocnemius muscle. Postoperatively the flap had to be re explored within the first 24 hours because of congestion. There was a collection of haematoma underneath the flap causing compression of the veins, which was evacuated. The patient recovered well subsequently and skin graft of the donor site was done two weeks later.

### Case report 2

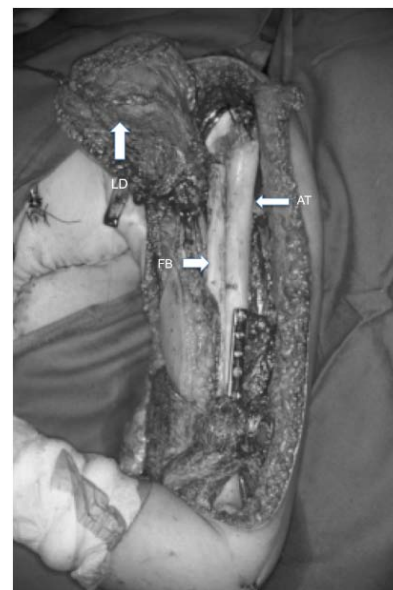
A 12 year old girl presented with a diagnosis of right humerus telangiectatic osteosarcoma She had neoadjuvant treatment with cisplatin and doxorubicin for 2 courses. Wide resection of the tumour resulted in a 35 cm bone defect and a 23×8 cm skin and soft tissue defects. Reconstruction was achieved with an allograft and an endoprosthesis augmented with a free osteoseptocutaneous fibula flap and a pedicle musculocutaneous latissimus dorsi flap ( Fig.2 ). The harvested fibula measured 29 cm with overlying 12×5 cm of skin flap. The peroneal artery and vein was anastomosed to the profunda brachii artery and its vena comitante. The latissimus dorsi skin paddle measured 12×5 cm. The fibula flap had to be re-explored after 24 hours because of the venous congestion. The flaps survived completely. Subsequent recovery was uneventful.

### Discussion

The most important principle in tumour surgery is complete tumour excision with histologically clear margins. The need to



**Fig 1:** Photo showing bilateral osteoseptocutaneous fibula flap harvested from patient 1.



**Fig 2:** Photo showing the surgical defect reconstructed with an allograft and endoprosthesis augmented with a vascularized osteoseptocutaneous fibula flap and a pedicled latissimus dorsi flap

reconstruct these, sometimes massive surgical defects have presented the reconstructive surgeon with the daunting task of devising ingenious ways for tissue coverage. This has to be accomplished as soon as possible to permit adequate healing and timely resumption of adjuvant treatment. When these defects are there in the extremities, the ability to cover the wounds and reconstruct the bony defect would also decide whether the limb salvage is possible or not. The resultant defect after surgery usually results in composite (skin, soft tissue, bone) deficiency and more than one

flap might be needed to replace these tissues. The use of double flap in the reconstruction of head and neck defects has been described previously (3,4). The reported aims of these combinations were coverage of extensive soft tissue defect, easier flap inseting and provision of a more specific inner lining that might not be achievable with the cutaneous portion of the vascularised bone flap (4).

The extensive composite defect encountered after tumour resection sometimes cannot adequately be reconstructed with a single flap. The three dimensional nature of the defect also need to be taken into account when planning the reconstructive procedure. Using a single flap in the reconstruction, the surgeon might have to compromise on leaving some exposed area to heal secondarily or risk flap failure with extra tension on the sutures. This may lead to extra morbidity on the part of the patient.

In this article, Patient 1 had a double microvascular composite tissue transfer reconstruction while the Patient 2 had a combination of one microvascular composite tissue transfer and one pedicle flap. This is because of the availability of a suitable flap in the regional area of reconstruction namely the latissimus dorsi flap when operating on the upper arm. The free fibula flap was used to bridge a bony defect. The vascularized fibula flap heals faster compared to bone allograft and is ideal in patients who require postoperative chemotherapy or radiotherapy or when there is a poor bed (5). Using well vascularized muscle to cover the allograft decreases the incidence of infection and non union and promotes faster wound healing (6). Vascularized bone grafts are ideal for large defects resulting from upper extremity tumour resection especially in young and active patients (1).

Treatment outcome can be described in terms of function of the salvage limb, aesthetic appearance and the patient's own psychological well-being in not having to go through an amputation. Limb sparing surgery for soft tissue sarcomas of the upper limb with microvascular tissue transfer has

been shown to expedite healing with no difference in recurrence rate and survival compared to amputation (7). Patient 2, with tumour affecting the upper limb had full use of her hand and elbow with limitation of movement only affecting the shoulder joints. However, studies have shown that lower extremity function has been more difficult to retain. This is attributed to the finding that lower extremity tumours were bulkier and detected later, necessitating larger resections and greater morbidity (8).

Whenever possible, immediate reconstruction is always preferred. It avoids multiple operative procedure with the associated increase in general anaesthesia, and also the increase in hospital stay and cost. Immediate reconstruction offers the option of earlier physical therapy and the resumption of adjuvant treatment hopefully contributes to improving the overall prognosis.

## References:

1. Rashid M, Hafeez S, Zia ul Islam M et al. Limb salvage in malignant tumours of the upper limb using vascularised fibula. *J of Plast Reconstr Aesth Surg* 2008 ;61:648-661.
2. Wright EHC, Gwilym S, Gibbons CLMH et al. Functional and oncological outcomes after limb-salvage surgery for primary sarcomas of the upper limb. *J of Plast Reconstr Aesth Surg* 2008;61:382-387.
3. Chen HC, Demirkan F, Wei FC et al. Free fibula osteoseptocutaneous-pedicled pectoralis major myocutaneous flap combination in reconstruction of extensive composite mandibular defects. *Plast Reconstr Surg*. 1999;103(3): 839-845.
4. Wei FC, Demirkan F, Chen HC et al. Double free flaps in reconstruction of extensive composite mandibular defects in head and neck cancer. *Plast Reconstr Surg* 1999; 103(1):39-47.
5. Kenneth L, Brown M D : Limb reconstruction with vascularized fibular grafts after bone tumour resection. *Clinical Orthop*. 1991; 262: 64-73.

6. Mastorakos P, Disa J, Athanasian E et al. Soft tissue flap coverage maximizes limb salvage after allograft bone extremity reconstruction. *Plast Reconstr Surg* 2002; 109 : 1567-73.
7. Barner-Rasmussen I, Popov P, Bohling T, Blomqvist C, Tukiainen E. Microvascular reconstruction after extensive soft tissue sarcoma resections in the upper limb. *European J Surg Oncology* 2010; 36:78-83.
8. Serletti J, Carras A, O'Keffe R et al. Functional outcome after soft tissue reconstruction for limb salvage after sarcoma surgery. *Plast Reconstr Surg* 1998; 102(5): 1576-83.