

## Case report

### Sand Bezoar: A Very Rare Cause of Intussusception

Azhar AH<sup>1</sup>(✉), Tarmizi MNM<sup>4</sup>, A. Rashidi<sup>2</sup>, H. Mastura<sup>3</sup>, MNG Rahman<sup>1</sup>

<sup>1</sup>Department of Surgery and <sup>2</sup>Department of Emergency Medicine Hospital Universiti Sains Malaysia, Kubang Kerian, Kelantan, Malaysia

<sup>3</sup>Department of Radiology and <sup>4</sup>Department of Surgery, Hospital Raja Perempuan Zainab II, Kota Bharu, Kelantan, Malaysia

#### Abstract

Intussusception is the most common cause of intestinal obstruction in the first two years of life. The cause is not apparent in most of the cases. Associated conditions that can result in intussusception include polyps, Meckel's diverticulum, Henoch-Schonlein purpura, lymphoma, lipoma, parasites, foreign bodies and viral enteritis with hypertrophy of Payer's patches. We hereby describe a rare case of sand bezoar induced intussusception in a 9-year-old school girl with pica (geophagia). A description of her presentation and management, along with a review of literature is being presented.

**Keywords:** Pica, intussusceptions, intestinal obstruction

#### Correspondence:

Dr. Azhar bin Amir Hamzah, Department of Surgery, School of Medical Sciences, Universiti Sains Malaysia, Health Campus, 16150 Kubang Kerian, Kelantan, Malaysia. Tel: +609-767 6774 Email: drazhar786@hotmail.com

Date of submission: 25<sup>th</sup> June 2011

Date of acceptance: 18<sup>th</sup> Sept 2011

Date of publication: 3<sup>rd</sup> Oct 2011

#### Introduction

Intussusception is a common cause of intestinal obstruction in children. The causes of intussusception are not well established. Most cases in young children are unknown. Viral and bacterial infections of the intestine were postulated as the possible causes of intussusception in infancy. In contrast, causes of intussusception in older children were believed to be due to polyps or tumors, which are often referred to as the "lead point" of the intussusception (1).

A medline review of the literature published between 1959 and July 2009 was performed using a combination of terms, including "PICA," "bezoar," and "intussusception". There were 17 related articles (2-18). The review of literature revealed few types of bezoar. The types of bezoar include lactobezoar, trichobezoar, food boli, phytobezoar and calcium phosphate bezoar. However, there was no case report on sand bezoar causing intussusception. This article

describes a rare case of pica (geophagia) associated with intussusception in a 9-year-old girl.

#### Case Report

A 9-year-old girl was brought to the Emergency Department because of abdominal pain and distension. She was apparently well until 5 days ago when she complained of sudden onset of central abdominal pain. Her abdominal pain was colicky in nature and associated with non projectile vomiting. She vomited mainly undigested food particles, no blood or fecal material. Her abdomen was distended and gradually increasing in size for the past 5 days. She had loss her appetite and became generalized fatigue. Her parents denied any change of bowel habits, fever or trauma. According to her parents, she performed poorly at school and had a habitual ingestion of sandy particle.

On clinical examination, she was dehydrated and in pain. Her vital signs were normal. Her abdomen was

distended markedly, tender on deep palpation and bowel sounds were absent. Her liver, spleen and kidneys were not palpable. No other mass was felt and there was no ascites.

Her full blood count, serum electrolytes and C-reactive protein results were within a normal range. Abdominal radiograph demonstrated large bowel loops dilatation and presence of sandy particles within the bowel loops and rectum (Figure 1).

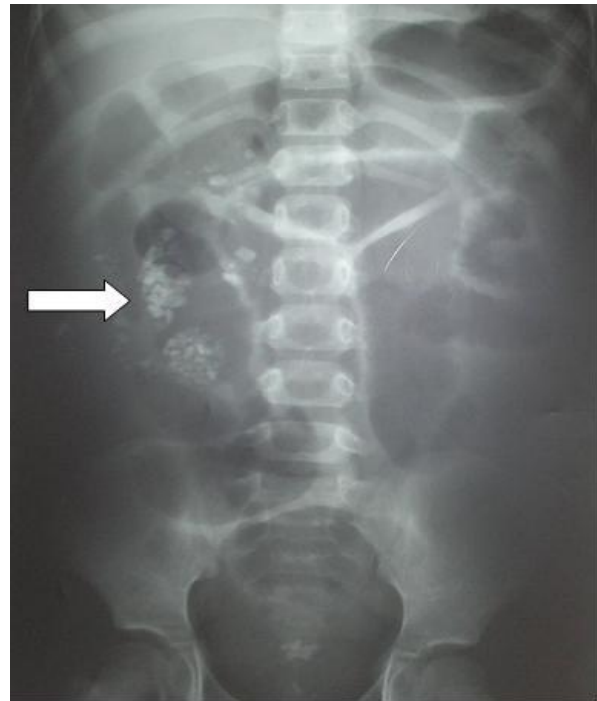
Urgent ultrasound of abdomen demonstrated 'pseudokidney sign' on longitudinal scan (Figure 2). Minimal free fluid was seen in between the bowel loops. A diagnosis of intussusceptions was made and she was subjected for emergency laparotomy. There was an ileocolic intussusception that in-vaginated into the descending colon. Right hemicolectomy and end-to-end anastomosis were done successfully. Post operatively, she recovered uneventfully. She was discharged home 5 days later with a referral letter to the Paediatric Psychiatrist for psychotherapy and counseling. Recent surgical follow up, she was healthy and the abdominal wound had healed.

## Discussion

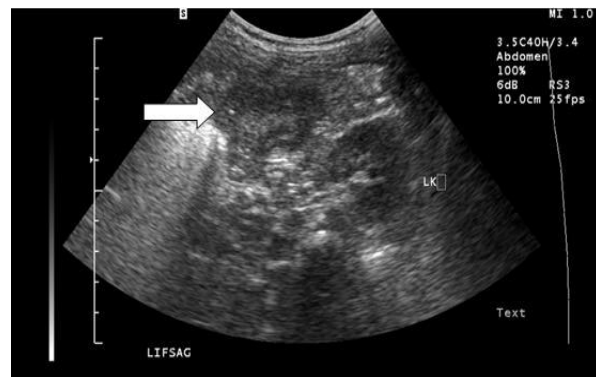This unfortunate girl had an intestinal obstruction secondary to intussusception. Intussusception usually occurs in children between 3 months and 6 years of age. It is extremely rare in children under 3 months of age or in older children (1). In our case, her unusual eating habit geophagia (consuming sandy particles) leads to the formation of intussusception. We postulate that the intussusception was initiated by the submucosal edema of intestinal wall or peristaltic dysrhythmias induced by sand bezoar. Complications of intestinal bezoar include chronic inflammation of the intestinal mucosa, bleeding, perforation, and peritonitis (19, 20).

Pica is described as persistent eating of non-nutritive substances for a period of at least one month. It is considered normal for children less than two years old to put anything in their mouth. After this age, eating non-food items is thought to be abnormal (21).

Pica is most frequently seen in small children, pregnant women, and individuals with learning disabilities and patients with chronic renal failure (22). It has been observed in 20% of pregnant women (23). The clues to pica as the underlying cause of abdominal complaints should not be neglected specially in patients who are known to be at higher risk of pica (23).



**Figure 1:** Showing dilated large bowel and sandy particles within the bowel loops (white arrow).



**Figure 2:** Showing a mass with reniform appearance, with a central hyperechoic region surrounded by a hypoechoic region, is located anteromedial to the normal appearing left kidney (white arrow).

The cause of pica is unknown but multi-factorial etiology is suggested. Some causes include iron deficiency, psychological factors like: poverty, maternal neglect and abuse, lack of parental supervision, disorganized family situation, mental retardation, autism and brain behavior disorders like Kleine-Levin syndrome (24 -27).

Pica can result in various gastrointestinal tract problems including obstructions, perforations, ulceration and constipation (28). Intestinal obstruction was the most common clinical presentation and ileum

was the most often the site reported at surgery. Perforation with peritonitis was the next common presentation (29).

Other reported complications of pica include parasitic infections such as toxoplasmosis and toxocarasis, abrasive tooth wear, lead poisoning from substances contained within the soil or other sources such as lead-based paints, hypokalemia and rhabdomyolysis (30 – 33).

In general, management of bezoar complicated with surgical abdomen is surgical intervention. There were few literatures discussing the alternative treatment for gastric bezoar removal. For example, endoscopic retrieval of gastric bezoars and extracorporeal shock wave lithotripsy and endoscopy with the use of laser ignition with miniexplosions has been suggested as alternative approaches (34,35). Laparoscopic removal of a large gastric trichobezoar has recently been described (36). We postulate that the similar techniques may be can be used to remove sand bezoar.

## References

- Jay L. Grosfell, James A. O'Neill, Arnold G. Coran. Paediatric Surgery. Vol. 2, 6<sup>th</sup> Edition, Philadelphia: Mosby Elsevier Publ, 2006, 1313-1321.
- Barzilai M, Peled N, Soudack MS, et al. Trichobezoars. Harefuah. 1998; 135(3-4): 97-101.
- Dalshaug GB, Wainer S, Hollaar GL. The Rapunzel syndrome (trichobezoar) causing atypical intussusception in a child: a case report. J Pediatr Surg 1999; 34(3): 479-80.
- Duncan ND, Aitken R, Venugopal S et al. The Rapunzel syndrome. Report of a case and review of the literature. West Indian Med J 1994; 43(2): 63-5.
- Fildes RD, Springate J.E, Jewett T, O'Shea M, et al. Colonic intussusception secondary to a calcium phosphate bezoar in a child receiving calcium carbonate for hyperphosphatemia. J Pediatr Surg 1989; 24(11): 1195-7.
- Godart B, Wangermez M, Doucet C, et al. Rapunzel syndrome associated with small bowel intussusception, acute pancreatitis and bile duct dilatation. Gastroenterol Clin Biol 2006; 30(11):1324-5.
- Gonzalez EC, Hernandez N, Santisteban M, et al. Trichophagia, trichobezoar, intestinal invagination and iron deficiency. An Esp Pediatr 1983; 19(4): 337-8.
- Gough MH. Multiple intussusception an intestinal perforation due to a bezoar. Br J Surg 1960; 48: 222-3.
- Harris VJ, Henley G. Unusual features and complications of bezoars in children. Am J Roentgenol Radium Ther Nucl Med 1975; 123(4): 742-5.
- Kibria R, Michail S, Ali SA.. Rapunzel syndrome-a rare cause of multiple jejunal intussusception. South Med J 2009; 102(4): 416-8.
- Levi WM. Gastro-intestinal trichobezoar: report of a case with intestinal obstruction secondary to jejunal intussusception. J S C Med Assoc 1959; 55(3): 94-6.
- Lynch KA, Feola PG, Guenther E. Gastric trichobezoar: an important cause of abdominal pain presenting to the pediatric emergency department. Pediatr Emerg Care 2003; 19(5): 343-7.
- Mehta M, Patel RV. Intussusception and intestinal perforations caused by multiple trichobezoars. J Pediatr Surg 1992; 27(9):1234-5.
- Memon SA, Mandhan P, Qureshi J.N, et al. Recurrent Rapunzel syndrome – A case report Med Sci Monit 2003; 9(9): 92-4.
- Rabie ME, Arishi AR, Khan A, et al. Rapunzel syndrome: The unsuspected culprit. World J Gastroenterol 2008; 14(7): 1141-3.
- Rees M. Intussusception caused by multiple trichobezoars: a surgical trap for the unwary. Br J Surg 1984; 71(9): 721.
- Rogers LF, Davis EK, Harle TS. Phytobezoar formation and food boli following gastric surgery. Am J Roentgenol Radium Ther Nucl Med 1973; 119(2): 280-90.
- Weiss M, Danoff DM, Wood BP. Radiological case of the month. Jejunojejunal intussusception caused by a trichobezoar with a tail. Arch Pediatr Adolesc Med 1998; 152(4): 403-4.

19. Pul N, Pul M. The Rapunzel syndrome (trichobezoar) causing gastric perforation in a child: A case report. *Eur J Pediatr* 1996; 155(1):18-19.
20. Sinzig M, Umschaden HW, Haselbach H, Illing P. Gastric trichobezoar with gastric ulcer: MR findings. *Pediatr Radiol* 1998; 28(5):296-9.
21. Parry-Jones B, Parry-Jones WL. Pica: symptom or eating disorder? A historical assessment. *The British Journal of Psychiatry* 1992; 160: 341-54.
22. Logi DG, Regenye GR, Miles M. Pica and iron deficiency anemia: A case report. *J Oral Maxillofacial Surg* 1992; 50(6): 633-5.
23. Anderson JE, Akmal M, Kittur DS. Surgical complications of pica: report of a case of intestinal obstruction and review of the literature. *Am Surg* 1991; 57(10): 663-7.
24. Horner RD, Lackey CJ, Kolasa K, Warren K. Pica practices of pregnant women. *J Am Diet Assoc* 1991; 91(1): 34-8.
25. Boris NW, Dalton R. Pica. In: Behrman RE, Kliegman RM, Jenson HB, editors. *Nelson textbook of Pediatrics*. 17th edition. New Delhi: Elsevier; 2004. p. 73-74.
26. Chatoor I. Feeding and eating disorders of infancy and early childhood. In Kaplan and Sadock's *Comprehensive textbook of psychiatry*. 8th edition. Philadelphia, Lippincott Williams and Wilkins; 2005. p. 3217-27.
27. Crosby WH. Pica, a compulsion caused by iron deficiency. *Br J Haematol* 1976; 34(2): 341-2.
28. Kapur D, Agarwal KN, Sharma S. Detecting iron deficiency anemia among children (9-36 months) by implementing a screening program in an urban slum. *Indian Pediatr* 2002; 39(7): 671-6.
29. Anderson JE, Akmal M, Kittur DS. Surgical complications of pica: report of a case of intestinal obstruction and review of the literature. *Am Surg* 1991; 57(10): 663-7.
30. Barker D. Tooth wears as a result of pica. *Br Dent J* 2005; 199(5): 271-3.
31. Mengel CE, Carter WA, Horton ES. Geophagia with iron deficiency anemia and hypokalemia. *Arch Intren Med* 1964; 114: 470-4.
32. Gonzalez JJ, Owens W, Ungaro PC, Werk EE, Wentz PW. Clay ingestion: A rare cause of hypokalemia. *Ann Int Med* 1982; 97(1): 65-66.
33. Saeed ZA, Ramirez FC, Hepps KS, et al. A method for endoscopic retrieval of trichobezoars. *Gastrointest Endosc* 1993; 39(5): 698-700.
34. Benes J, Chmel J, Jodl J, Stuka C, Nevorál J. Treatment of a gastric bezoar by extracorporeal shock wave lithotripsy. *Endoscopy* 1991; 23(6): 346-8.
35. Ying-cai H, Zhong-he G, Ying G, et al. Endoscopic lithotripsy of gastric bezoars using a laser-ignited mini-explosive device. *Chin Med J* 1990; 103(2):152-5.
36. Nirasawa Y, Mori T, Ito Y, Tanaka H, Seki N, Atomi Y. Laparoscopic removal of a large gastric trichobezoar. *J Pediatr Surg* 1998; 33(4): 663-665.