

Case Quiz

Christopher CK Ho

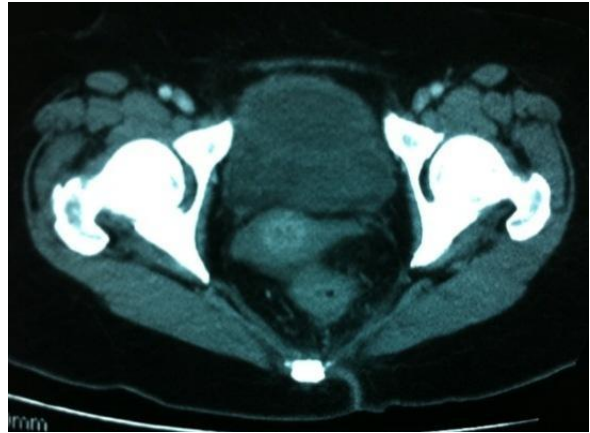
Department of Surgery, Universiti Kebangsaan Malaysia Medical Centre, Jalan Yaacob Latif, Bandar Tun Razak, 56000 Cheras, Kuala Lumpur, Malaysia

Case Quiz

A 60-year-lady complained of abdominal discomfort and discharge from the umbilicus for the past 1 month. There was occasional haematuria and mucusuria. However, there was no frequency or dysuria.

On examination, she was cachexic but vital signs were stable. She was afebrile. The abdomen was mildly distended and there was a vague suprapubic mass which was mildly tender. There was serous discharge seen at the umbilicus.

A CT scan of the abdomen/pelvis was performed (See figures).



Having read the above case, answer the following:

1. What is your final diagnosis?
2. What is the embryological aspect involved with this condition?
3. What is the management for this lady?

The response may be e-mailed to the address mentioned below. The correct answer along with the names of all correct entries will be published in the next issue of JSA.

Editor, Journal of Surgical Academia
E-mail: jsurg.academia@gmail.com

