

## Case Report

# Presence of Additional Head of Pronator Teres Muscle and Associated Neurovascular Variations: A Rare Case Report

Sushma RK<sup>1</sup>, Srinivasa RS<sup>2</sup>, Kumar MR Bhat<sup>1</sup> (✉)

Department of Anatomy, <sup>1</sup>Kasturba Medical College, <sup>2</sup>Melaka Manipal Medical College, Manipal University, Manipal-576104, Karnataka, India

### Abstract

Arm is a site for frequent injuries and it is involved in many surgical procedures. Variations in the arm have immense clinical significance. During the dissection of a right upper limb, brachial artery was found to divide into radial and ulnar arteries, 3cm above the inter-epicondylar plane. The ulnar artery and the median nerve were then passing through a tunnel formed by an extensive additional humeral head of the pronator teres muscle. Two centimetres long fibromuscular tunnel formed by the humeral head of the pronator teres was found to arise from the medial intermuscular septum and also from the fibrous arch from the shaft of the humerus to the medial intermuscular septum. In the same cadaver, the superior ulnar collateral artery was found to arise from the profunda brachii artery which is otherwise a branch of the brachial artery. Accurate knowledge of these variation patterns is of considerable clinical significance in conduct of surgeries of arm, fracture management of humerus and diagnosis of various compressive neuropathies.

**Keywords:** Brachial artery, fibro muscular tunnel, pronator teres, pronator syndrome, superior ulnar collateral artery.

### Correspondence:

Dr. Kumar MR Bhat, Department of Anatomy, Kasturba Medical College, Manipal University, Manipal-576104, Karnataka, India. Tel: +91-820-2922327 Fax: +91-820-2570061 Email: kumar.mr@manipal.edu

Date of submission: 31 Aug, 2012

Date of acceptance:

### Introduction

The brachial artery is a continuation of the axillary artery from the distal border of the teres major tendon and ends about a centimeter distal to the elbow joint by dividing into the radial and ulnar arteries. The artery is wholly superficial, covered anteriorly by skin and fascia and crossed superficially by the median nerve from the lateral to medial side. The brachial artery provides the following branches: profunda brachii, muscular and nutrient branches, superior and inferior ulnar collateral arteries, radial and ulnar arteries.

Normally, the pronator teres muscle arises as two heads, a humeral head arising just proximal to the medial epicondyle from the common tendon of the flexor muscles and an ulnar head from the medial side of the coronoid process. The median nerve enters the forearm between the two heads of the pronator teres.

Here we report a high division of brachial artery and an unusual fibromuscular tunnel formed by an extensive additional head of pronator teres. The latter finding is extremely rare and not reported elsewhere.

### Case Report

Variations were observed in a 60 year old male cadaver during routine dissection in the Department of Anatomy, Kasturba Medical College, Manipal, India. In this arm, the brachial artery was divided into radial and ulnar artery 3cm above the inter-epicondylar plane. The radial artery was seen descending medial to the biceps brachii and in the cubital fossa below the bicipital aponeurosis and follows the normal course in the forearm. The median nerve which normally crosses brachial artery from lateral to medial side is not seen and the nerve lies medial to brachial artery and ulnar artery in its course in the distal end of the arm. Then,

the ulnar artery and the median nerve were seen to pass through 2cm long tunnel formed by the extensive additional humeral head of the pronator teres muscle. A fibromuscular tunnel was so formed by the humeral head of the pronator teres which was arising from the medial intermuscular septum and also from the fibrous arch between the shaft of the humerus and medial intermuscular septum (Fig. 1). After running in the tunnels for about 2cm, the median and ulnar artery were emerging into the cubital fossa just below the inter-epicondylar plane under the additional head of the pronator teres muscle (Fig. 1).

Additionally, the profunda brachii artery, arising from the brachial artery immediately divided into middle and radial collateral arteries. Just before these two branches enter the lower triangular space, the superior ulnar collateral artery was found arising from the middle collateral artery and had a normal course with the ulnar nerve. This kind of origin of superior ulnar collateral artery was not reported earlier. However, the superior ulnar collateral artery found arising together with the profunda brachii or from a common trunk from the axillary and brachial arteries have been reported (1).

## Discussion

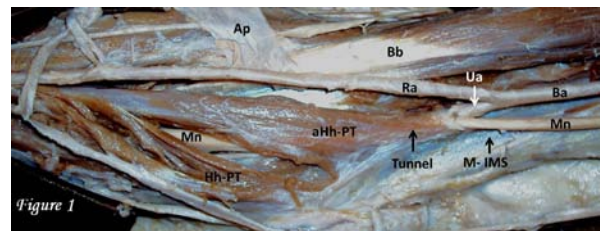
Muscular and arterial variations in the upper limb have varied clinical and surgical significance. Major variation were found in the brachial artery in about 25% of subjects studied (1). The bifurcation of brachial artery proximal to intercondylar line of humerus is considered a variation (2). The high division is possible at any point in the normal course of the vessel but, is more common in the middle third. The two branches, into which the brachial artery divides, retrace the usual position of the brachial artery. Further, cubital region onwards, these two arteries follow their normal course (2).

In the present case, we have focused on the morphology of this arterial variation and also discussed its clinical significance and relevance.

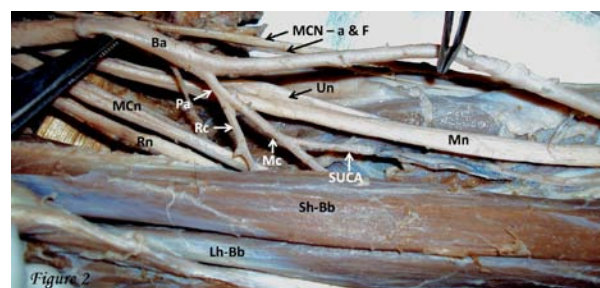
Earlier, it has been shown that the brachial artery divides into radial and ulnar artery in the arm itself after giving rise to profunda brachii artery (3). In another case, it has been reported that the brachial artery divided into superficial and deep branches. The superficial brachial artery was then divided into radial and ulnar arteries, while the deep division continued as interosseous artery and provided a large median artery which then completes the superficial palmar arch with the ulnar artery in the palm (4). An accessory brachial artery which arose from brachial artery 21cm proximal to the intercondylar line was also encountered (5). Thus, high origin of radial and ulnar artery is the most common type of variations in the brachial artery.

Embryological explanation provided to the higher origin of radial and ulnar arteries is the regression of primitive axial artery and the proximal part of superficial brachial-radial artery resulting in such anomalies (6).

In this case we also report that, the profunda brachii artery, arising from the brachial artery immediately divided into middle and radial collateral arteries. The superior ulnar collateral artery was found arising from the middle collateral artery which later had a normal course with the ulnar nerve. This kind of origin of superior ulnar collateral artery was not reported earlier. However, the superior ulnar collateral artery found arising together with the profunda brachii or from a common trunk from the axillary and brachial arteries have been reported (1).



**Figure 1:** Brachial artery (Ba) is divided into Radial (Ra) and Ulnar arteries (Ua) in the lower end of the arm itself. Then the Ulnar artery and the Median nerve (Mn) passes through a tunnel formed by the extensive additional humeral head of the pronator teres muscle (aHh-PT). A fibromuscular tunnel formed by the humeral head of the Pronator teres was found arising from the medial intermuscular septum (M-IMS) and also from the fibrous arch form the shaft of the humerus to the medial intermuscular septum. Bb=Biceps Brachii; Ap=Reflected Bicipital aponeurosis.



**Figure 2:** Profunda brachii artery (Pa) was arising from the brachial artery and was immediately divided into Middle (Mc) and Radial (Rc) collateral arteries. The Superior Ulnar Collateral Artery (SUCA) was found arising from the middle collateral artery. Ba=Brachial artery; UN=Ulnar nerve; Mn=Median nerve; Sh-Bb=Short head of the biceps brachii; Lh-Bb=Long head of the biceps brachii, (MCN=a & f=Medial cutaneous Nerve of arm and forearm.

The vessels of the upper limb are frequently used for cardiac catheterization and awareness of such variations may therefore help to avoid any inadvertent injury and confusion during the procedure. Knowledge of higher division of brachial artery and anomalous origin of the superior ulnar collateral artery may be important during amputation and re-implantations. Variation in the branching pattern of the brachial artery is of significance in pedicle flaps, or arterial grafting. As it is tedious and expensive to identify the abnormal arterial pattern in a patient before surgery, physicians should be therefore aware of this possibility before initiating the procedure.

Brachial artery along with the median nerve is shown to pass posterior to the supracondylar process of humerus from which a fibrous arch covers the artery. Rarely, brachial artery is shown to cross by the muscular or tendinous slips from coracobrachialis, biceps, brachialis or pronator teres. The undivided brachial artery was also reported passing between the heads of pronator teres (7).

Here, in this case, the ulnar artery and the median nerve were seen to pass through a tunnel formed by the extensive additional humeral head of the pronator teres muscle. A fibromuscular tunnel formed by the humeral head of the pronator teres was found arising from the medial intermuscular septum and also from the fibrous arch from the shaft of the humerus to the medial intermuscular septum. This condition is extremely rare and not reported elsewhere.

The tunnel so formed may lead to the compression of the underlying structures especially the median nerve, as signified by the "Pronator Syndrome (PS)". The median nerve may also be compressed by the ligament of Struthers, bicipital aponeurosis, pronator teres, and the arch of the flexor digitorum superficialis (8). Earlier it has been reported that the median nerve passes between the superficial and deep heads of the pronator teres (80%), behind both heads (4.6%) and through the deep head (1.8%) of cases (9). In spite of this variability, most cases of PS are mainly caused by fibrous bands that compress the median nerve as it passes between the 2 heads of the pronator teres (10). In about 9.2% of cases studied, entrapped median nerve between the heads of the pronator teres was found to be the cause of median nerve compression (11).

The present finding where the long fibromuscular tunnel for the median nerve and the ulnar artery is new addition to the etiology for pronator syndrome and may also be the reason for "double crush syndrome". In Double crush syndrome, the median nerve may be compressed at multiple sites along the course of a

nerve and may result in symptomatic compressive neuropathy due to cumulative compression effect (12). Pronator syndrome is considered rare, especially in comparison to Carpel Tunnel Syndrome (CTS). In case of ineffective CTS treatment, other probable sites of median nerve compression must be considered. Thus, our finding may be important in surgical intervention for such double compressions.

### Conclusion

Accurate knowledge of these variations will be of considerable clinical significance while conducting the surgeries of arm, fracture management of humerus and diagnosis of various compressive neuropathies.

### References

1. Bergman RA, Thompson SA, Afifi AK, Saadeh FA. Compendium of human anatomic variation. Baltimore: Urban & Schwarzenberg, 1988,73-74.
2. Karlsson S and Niechajev IA. Arterial anatomy of the upper extremity. Acta Radiologica Diagnosis 1982; 23: 115-121.
3. Celik H, Germus G, Aldur MM, Ozcelik M. Origin of the radial and ulnar arteries: variation in 81 arteriograms. Morphologie 2001; 85: 25-27.
4. Vare AM, Bansal PC. A case of anomalous brachial artery and other associate vascular anomalies in a single upper limb. Journal of Anatomical society of India 1969; 18(2): 50-53.
5. McCormack LJ, Cauldwell, Anson BJ. Brachial and antebrachial arterial patterns. Surg Gynecol Obstet 1953; 96:43-54.
6. Srijit D, Shashi S, Shipra P. Double profunda brachii and abnormal branching pattern of the brachial artery. Timisoara Medical Journal 2005; 55(2):159-161.
7. Hofer K & Hofer G. Ueber den Verlauf der arteria brachialis mit dem nervus medianus zwischen den beiden kopfen des musculus pronator teres. Anatomical Anzeles 1910; 36:510.
8. Lee MJ, LeStayo PC. Pronator syndrome and other nerve compressions that mimic carpal tunnel syndrome. J Orthop Sports Phys Ther 2004; 34(10): 601-609.
9. Nebot-Cegarra J, Perez-Berruezo J, Reina de la Torre F. Variations of the pronator teres muscle:

- predispositional role to median nerve entrapment. Arch Anat Histol Embryol 1991;74:35-45.
10. Rehak DC. Pronator syndrome. Clin Sports Med 2001;20:531-540.
  11. Gessini L, Jandolo B, Pietrangeli A. Entrapment neuropathies of the median nerve at and above the elbow. Surg Neurol 1983;19:112-116.
  12. Childs SG. Double crush syndrome. Orthop Nurs 2003;22:117-121.