

Case Report

Jejunal Leiomyoma Presenting as Intussuception

Paras KP (✉)¹, Pankaj KG², Ashwani K², Parul KG³, Ashish K², Nikhil M²

¹Department of Surgery, Government Medical College, Amritsar, Punjab, 143001 India.

²Department of Surgery, ³Department of Pathology, Rajindra Hospital and Government Medical College, Patiala, Punjab, 147001, India.

Abstract

Tumors of the small intestine are rare. Even though the small bowel accounts for 80% of the length and 90% of the mucosal surface of the gastrointestinal tract, only 3% to 6% of gastrointestinal tumors and 1% of gastrointestinal malignancies arise from the small bowel. Leiomyoma, adenoma, lipoma, haemangioma, fibroma and hamartoma of the small intestine are considered to be benign neoplasm. Most small bowel tumors are incidental findings at operation or autopsy. Here we present a case of benign tumour of the small intestine, histologically diagnosed as leiomyoma, presented in Surgery Emergency Ward with intestinal obstruction, treated conservatively with no improvement and hence subjected to emergency exploratory laparotomy which revealed intussusception and leading cause of which was a benign leiomyoma. The literature is revised emphasizing issues of pathophysiology, specific characteristics and the treatment of this tumour.

Keywords: Benign tumour, intestinal obstruction, intussuception, jejunum, leiomyoma.

Correspondence:

Dr. Paras K Pandove, #38, Hem Bagh, Officer's Enclave, Patiala, Punjab, India 147001. Tel no: +919814507559 Fax: 01752226855
Email: drpandovepk@yahoo.co.in

Date of submission: 11 Nov, 2012

Date of acceptance: 7 Feb, 2013

Introduction

Neoplasms of the small intestine represent 3% to 6% of the tumours of the gastrointestinal tract and less than 2% of all tumours (1). Benign tumours of the small intestine are estimated to be 10% of all nonmalignant tumours of the gastrointestinal tract and 30% of all the neoplasms of the small intestine (2,3,4). Leiomyoma, adenoma, lipoma, haemangioma, fibroma and hamartoma of the small intestine are considered to be benign neoplasm (5,6,7). These neoplasms are usually seen after the fifth decade of life with a peak incidence between 70 to 80 years of age (6). We report an interesting case of a benign jejunal leiomyoma causing intussuception.

Case Report

A 55-year-old male was admitted to the emergency surgery ward of Rajindra hospital, Patiala with acute abdominal pain and distension. The pain was diffuse,

recurrent, dull in nature associated with anorexia, vomiting and constipation for the last five days. On examination, the abdomen was distended with generalized tenderness. On auscultation, the bowel sound was absent. The ultrasound examination revealed fluid collection in the pelvis. The patient was managed conservatively for two days, however he continued to have vomiting and increasing abdominal pain. There was no improvement in the symptoms, so he was subjected to an emergency operation. Exploratory laparotomy revealed the presence of a jejuno-jejunal intussuception. Following manual reduction, there was a tumor palpable at mid-jejunum (as the lead-point causing intussuception) with healthy small intestine except for mild congestion of the reduced portion. The tumour was brownish in color, firm in consistency, measuring 1.5cm in diameter, near the mesenteric border of the bowel and occupying almost the whole intestinal lumen (Fig.1). Segmental resection of the small intestine with tumour free margin was performed with end-to-end anastomosis

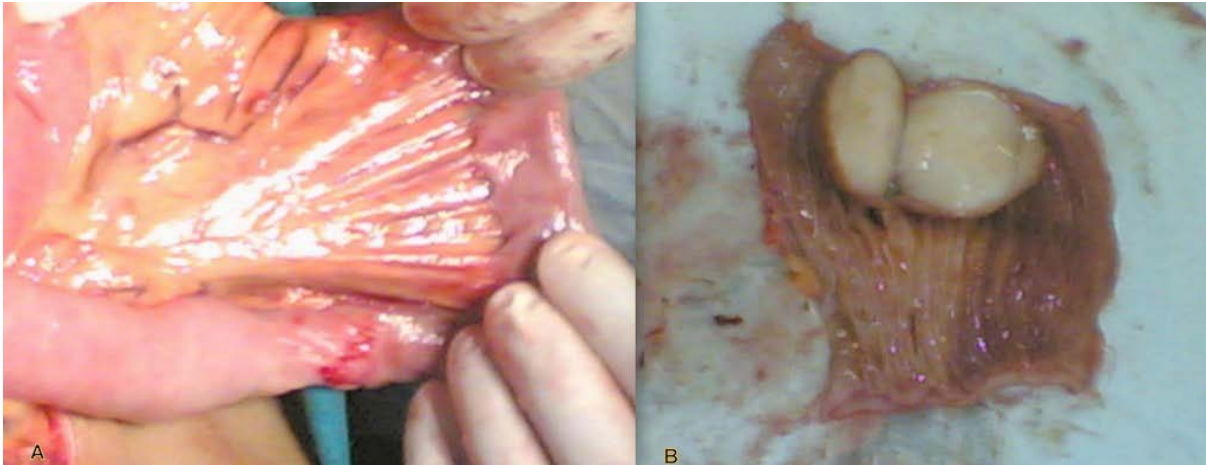


Figure 1: A) Intra-operative view of small gut (jejunum) showing long vascular arcade of jejunum and serosal surface of leiomyoma after manual reduction of intussusception. B) Intramural cut section of the jejunal leiomyoma.

was done. Surgical exploration of the abdominal cavity failed to reveal any other abnormality

Histology revealed an intestinal leiomyoma with no malignant evidence (Fig. 2). The postoperative course of the patient was uneventful and the patient was discharged on the 15th postoperative day. (Because our patients prefer to stay till the sutures are removed.) Patient is doing well after the discharge and is on regular follow-up.

Discussion

Tumours of the small intestine are rare. Even though the small bowel accounts for 80% of the length and 90% of the mucosal surface of the gastrointestinal tract, only 3% to 6% of gastrointestinal tumors and 1% of gastrointestinal malignancies arise from the small bowel. Most small bowel tumors are incidental findings at operation or autopsy. Smooth muscle tumors of the gastrointestinal tract can be classified as leiomyomas, leiomyosarcomas and high grade leiomyosarcomas, depending on the cytological atypia and mitotic rate.

It is usually diagnosed in the fifth decade of life, although it may occur at any age. There is no sex predilection. Though most common in jejuno-ileal, there has been a disproportionately high incidence of smooth muscle neoplasm in Meckel's diverticula, followed by the duodenum, if the unit area is considered. The distribution of these tumours in the alimentary tract, in the study from Taiwan in 1995,(8) in decreasing order of frequency, were found in the stomach (40%), jejunum (20%), ileum and rectum (14.3% each), duodenum (8.57%) and esophagus (2.86%).

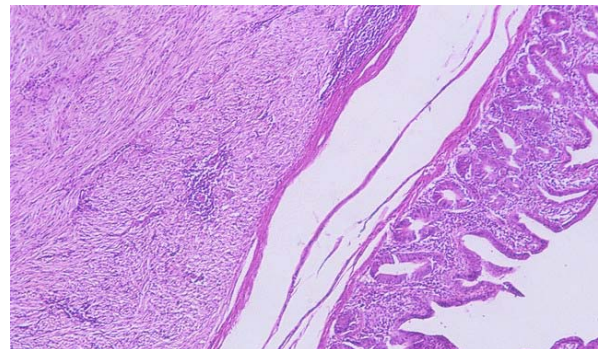


Figure 2: Photomicrograph of leiomyoma showing the whorling pattern of smooth muscles and normal intestinal tissue.

Leiomyomas are usually single, firm, grayish-white, well defined masses. They are often umbilicated with a central ulceration and are covered with normal epithelium. Four different growth patterns are observed; intra-luminal, intra-mural, extra-luminal, and dumb-bell shaped (9).

Microscopically, leiomyomas consist of bundles of well-differentiated smooth muscle with no evidence of mitosis. The absence of mitosis is a critical parameter in ruling out malignancy (leiomyosarcoma). As seen in the present case, a section through wall of intestine revealed cellular tumour replacing the various coats of the intestine, including the mucosa. Because of the bundle arrangement and the predominating type of the long rod-shaped nucleus, the growth is considered to arise from the muscular coats of intestine with no evidence of mitosis.

Most leiomyomas remain asymptomatic and are found incidentally at autopsy. As these tumours tend to be

highly vascular and ulcerate, Gastrointestinal (GI) bleeding is the most frequent presentation (75%), particularly in the duodenum. Whereas, only 25% present with obstructive symptoms like intra-luminal growth and compression or intussuception. The various clinical presentations are gastrointestinal bleeding (43.8%), abdominal mass (37.5%), abdominal pain (21.3%) and obstruction (16.4%). No symptom or sign were evident in 8.8% of the cases studied. (8)

In a recent study of 1074 patients with leiomyomas, intussuception was a common finding, with ileal tumors occurring in about 40% of the patients (10) but jejunal leiomyomas causing intussuception as in the present case is a rare entity which has not been reported in literature.

Pre-operative diagnosis of jejunal leiomyomas is difficult, partly owing to their rare occurrence and partly to the lack of any pathognomonic signs. The treatment of jejunal leiomyoma is segmental resection with clear margins. Leiomyomas are difficult to differentiate from leiomyosarcomas, even on pathological examination. Lymph node resection is not routinely required because even leiomyosarcoma does not spread via lymphatics.

Conclusion

Leiomyomas of the gastrointestinal tract is infrequent and usually found incidentally at autopsy. If symptomatic, may present with GI bleeding. Intussuception was a common finding, with ileal leiomyomas but jejunal leiomyomas causing intussuception is not reported in literature. Preoperative diagnosis is difficult to make owing to the absence of specific clinical symptoms and difficulties in radiologic evaluation of small bowel. Furthermore, the rarity of the condition does not allow any one surgeon or center to gain sufficient expertise. Hence, this rare diagnosis of jejunal leiomyoma should be kept in mind while dealing with small intestinal obstruction.

References

1. Norberg KA, Emas S. Primary tumours of small intestine. *Am J Surg* 1981; 142(5): 569-573.
2. Zhang WL. Primary tumour of the small intestine. Analysis 102 patients. *Zhonghua Zhong Liu Za Zhi* 1988; 10(5): 370-2.
3. Giuliani A, Caporale A, Teneriello F, Alessi G, Serpieri S, Sammartino P. Primary tumours of the small intestine. *Int Surg* 1985; 70(4): 331- 334.
4. Croeninger J, Georgi M. Tumours of the small intestine-clinical signs and symptoms, diagnosis and therapy. *Leber Magen Darm* 1977; 7(2): 75-83.
5. Ashiey SW, Wells Jr SA. Tumours of the small intestine. *Semin Oncol* 1988; 15(2): 116-28.
6. Burgos AA, Martinez ME, Jaffe BE. Tumours of the small Intestine. In: Zinner MJ, Schwartz SI, Ellis H: *Maingot's abdominal operations*, Vol. I, Tenth ed. Appleton & Lange, Connecticut 1997, pp 1173-1184.
7. González J, Marco A, Andújar M, Iñiguez L. Myoepithelial hamartoma of ileum: A rare cause of intussuception in children. *Eur J Pediatr Surg* 1995; 5(5): 303-304.
8. Chou FF, Eng HL, Sheen-Chen SM. Smooth muscle tumours of the gastrointestinal tract: Analysis and prognostic factors. *Surgery* 1996; 119(2): 171-7.
9. Blanchard DK, Budde JM, Hatch III GF et al. Tumors of the small intestine. *World J Surg* 2000; 24(4): 421-9.
10. Gong F, Swain P, Mills T. Wireless endoscopy. *Gastrointest Endosc* 2000; 51(6): 725-729.