

Original Research Article**The Great Saphenous Vein- An Anatomical Study**

Mamatha H, D'Souza AS, Sriprajna, Sushma RK (✉)

Department of Anatomy, Kasturba Medical College, Manipal University, Manipal- 576104, India.

Abstract

The anatomical variations are more frequently encountered in the venous system particularly in the superficial veins when compared to the arterial system. The great saphenous vein is the longest vein of the body and represents pre-axial vein of lower limb. The venous anatomy is of great importance to the surgeons and sonographers. The present study included 25 lower limbs during routine dissection for undergraduate students in the Department of Anatomy, Kasturba Medical College, Manipal. We studied the great saphenous vein with reference to its formation, relation with the medial malleolus, distance from patella, level of termination and variation in its major tributaries. The findings were recorded, tabulated and photographed. Aforementioned anatomical facts including mode of termination of great saphenous vein can be important for surgeons planning intervention in this area. This vein is used as an arterial graft because of the marked anatomical remodeling. Thus, a good understanding of the typical ultrasound appearance of the great saphenous vein, its relationship to the major bony landmarks is significant.

Keywords: Great saphenous vein, femoral vein, varicosity, bypass graft, medial malleolus, pubic tubercle, patella

Correspondence:

Sushma RK, Department of Anatomy, Kasturba Medical College, Manipal University, Manipal - 576104, India. Tel: +91-820-2922327 Fax: +91-820-2570061 Email: sushma.rk@manipal.edu

Date of submission: 1 Oct, 2013

Date of acceptance: 13 Mar, 2014

Introduction

The venous drainage of the lower limb varies considerably in its arrangement from subject to subject and even from limb to limb (1). It is divided into superficial and deep venous systems. The superficial venous system is represented by the great saphenous (long saphenous), the small saphenous (lesser saphenous), and their tributaries.

The great saphenous vein (GSV) is the longest vein of the body and represents the pre-axial vein of lower limb. It is the most important superficial vein of the lower extremity which begins as a continuation of the medial side of the dorsal venous arch in the foot supplemented by the medial marginal vein. The vein passes upwards about 2.5cm anterior to the tibial malleolus, and then ascends about a finger's breadth behind the medial border of tibia to reach the knee. It occupies the postero-medial aspect of the knee joint about one hand breadth posterior to the patella and runs

upwards along the medial side of the thigh to reach the saphenous opening, which lies about 3cm below and lateral to pubic tubercle and finally drains into the femoral vein after piercing the femoral sheath (1).

Several authors have reported the variations possible in the tributaries and course of the great saphenous vein. However, no light has been focused on the possible measurements of the great saphenous vein in relation to the major bony prominences to which it is related. Understanding the venous anatomy is essential for surgeons, cardiologists and radiologists and would play an important role in the diagnosis and management of different venous diseases.

Materials and methods

The study was carried out in the Department of Anatomy, Kasturba Medical College, Manipal. The study included 25 cadavers (20 males and 5 females) of age ranging between 45-60 years.

History of the cadavers showed no major abnormalities. The lower limbs of the cadavers were dissected bilaterally (50 specimens). After removal of the skin flap, the superficial fascia was cleared; the great saphenous vein and its major tributaries were identified and painted.

The vein was then studied with reference to various important land marks. The distance of the formation of the dorsal venous arch from the maximum elevated point of the medial malleolus, distance of the great saphenous vein from the medial malleolus, distance of the great saphenous vein from the medial edge of the patella, distance of termination of the great saphenous vein from the pubic tubercle were the considered measurements. All the measurements were carried out using digital Vernier calipers uniformly in all the cadavers to remove any bias. Variations in the termination of the great saphenous vein were also noted. The findings were tabulated and photographed.

Results

1. Distance of the formation of the Dorsal Venous arch from the maximum elevated point of the medial malleolus (Fig. 1).

Cases	Formation
25 (50%)	4cm
12 (24%)	3cm
10 (20%)	6cm
3 (6%)	7cm

2. Distance of the Great saphenous vein from the medial malleolus (Fig. 2).

Cases	Distance from medial malleolus
30 (60%)	3cm
16 (32%)	2cm
4 (8%)	3.5cm

3. Distance of the great saphenous vein from the medial edge of the patella (Fig. 3).

Cases	Distance from the medial edge of the patella
28 (56%)	10cm
10 (20%)	8cm
6 (12%)	7cm
6 (12%)	5cm

4. Distance of termination of the great saphenous vein from the pubic tubercle (Fig. 4).

Cases	Termination
26 (52%)	3.5cm
8 (16%)	2.5cm
12 (24%)	4cm
4 (8%)	5cm

Additionally double saphenous vein was encountered in two cases. Both the veins were seen to drain separately into the femoral vein (Fig. 5).

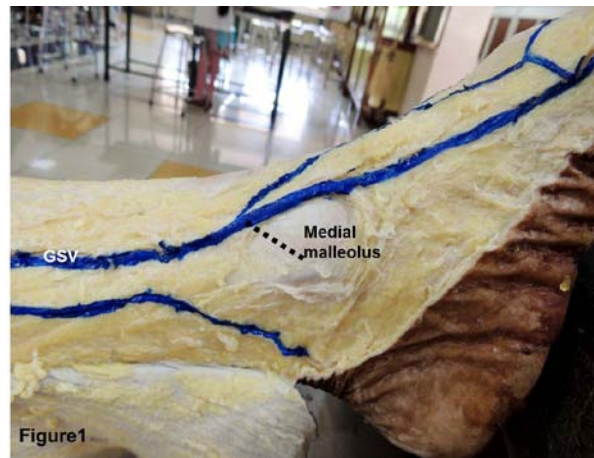


Figure 1: Showing the measurement of the distance (dotted line) of the formation of the Dorsal Venous arch from the maximum elevated point of the medial malleolus. GSV- Great saphenous vein.

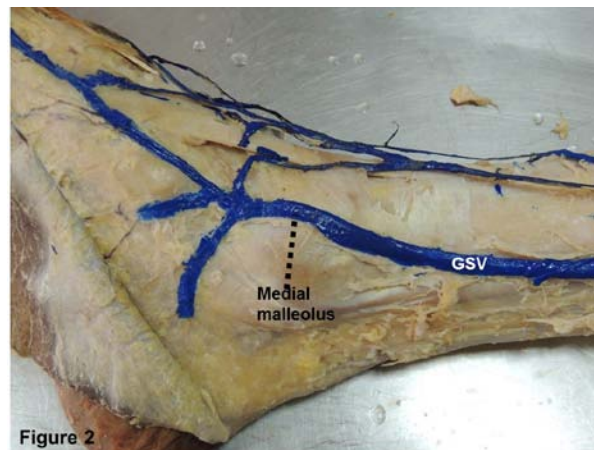


Figure 2: Showing the measurement of the distance between the great saphenous vein (GSV) and the medial malleolus.

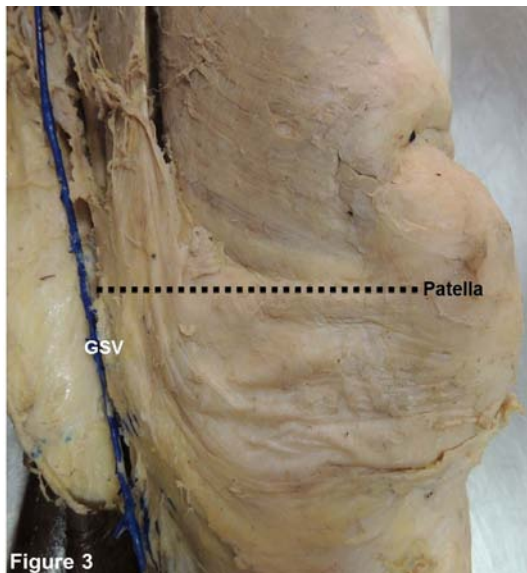


Figure 3: Showing the distance of the great saphenous vein (GSV) from the medial edge of the patella

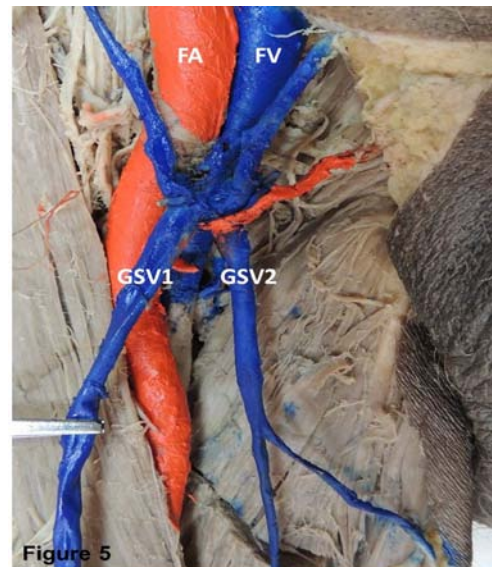


Figure 5: Showing double saphenous vein draining into femoral vein. GSV1 & 2- Great saphenous vein

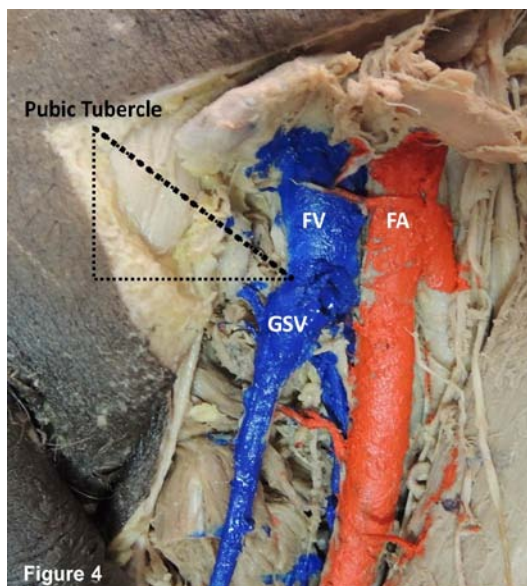


Figure 4: Showing the distance of termination of the great saphenous vein (GSV) from the pubic tubercle

Discussion

Frequent anatomical variations in the venous system make it more inconstant when compared to the arterial system (2,3). The great saphenous vein, the longest vein in the body, begins as a continuation of the medial marginal vein of the foot, courses upwards and drains into the femoral vein distal to the inguinal ligament. The vein in its course may be highly variable both in its distance from the major bony

landmarks and its tributaries. Variability has been observed in the reported incidence of tributaries, duplicated or accessory great saphenous vein (4). However there is very little amount of data in the medical literature describing the relationship of the vein with the major bony landmarks which are important in different surgical approaches.

The distance of the formation of the Dorsal Venous arch from the maximum elevated point of the medial malleolus when noted showed variability. The distance was about 4cm in majority of the cases (50%). However, no reports were found to support the findings.

Usually, the GSV ascends 2.5 – 3 cm anterior to the tibial malleolus, crosses the distal third of the medial surface of the tibia obliquely to its medial border, then ascends a little behind the border of the knee (1,2). In the present study, most of the cases were within the normal limits. But 8% of the cases showed a variable distance of 3.5cm from the media malleolus.

Proximally, it is postero-medial to the medial tibial and femoral condyles, lying about a breadth of the subject's hand (6.25 -10 cm) posterior to medial edge of the patella. It then ascends in the medial aspect of the thigh (1, 2). The present case showed that in 56% of the cases, the distance was 10cm, 8cm in 20%, 7cm in 12% and 5cm in the remaining 12% of the cases. The latter finding is unusual and is of clinical significance.

The GSV then passes through the saphenous opening and finally opens into the femoral vein. The 'center' of the opening is often said to be 2.5-3.5 cm inferolateral to the pubic tubercle (1, 2). However, the present study showed that in 12% of the cases, the distance was 4cm and 5cm in 8% of the cases respectively. The measurements of the remaining cases were within the normal limits.

Variations in the formation, course and tributaries of the saphenous vein are common (2,3). Authors reported the existence of double GSVs (5,6). In the present study two specimens showed unilateral double GSV close to their termination. Both the veins were seen to drain separately into the femoral vein. The anatomical variations of the saphenous-femoral junction have to be well understood as it is essential in managing the patients with varicose veins. Failure to appreciate these variations may hamper the varicose vein surgery.

Recently, the line of treatment for varicose veins has observed significant changes to meet the concerns of the surgeons and patients regarding the cosmetic results and preservation of the saphenous vein for future cardiac or peripheral arterial bypasses (7). To simplify the treatment of varicose veins, minimally invasive techniques have been evolved (8,9,10). Therefore, venous system has to be properly evaluated for the treatment of various disorders.

Regarding procedures like coronary artery bypass grafts usually the segment of the saphenous vein closer to the ankle joint is preferred (6). Therefore, the relationship of the GSV with the major bony landmarks gains utmost importance.

Conclusion

A fore mentioned anatomical facts including mode of termination of great saphenous vein can be of importance for surgeons planning intervention in this area. This vein can also be used as an arterial graft because of its easy accessibility. Therefore, a good understanding of the appearance of the great saphenous vein and its relationship to the major bony prominences is important.

References

1. Standring S, Borley NR, Collins P, Crossman AR et al. Gray's Anatomy. The Anatomical Basis of Clinical Practice. 39th edition. Philadelphia: Elsevier Churchill Livingstone, 2005, pp-724-8, 1359.
2. Bergman RA, Thompson SA, Afifi AK, Saadeh FA. Compendium of human anatomic variation. Baltimore: Urban & Schwarzenberg, 1988, pp- 93.
3. Caggiati A, Bergan JJ, Gloviczki P, Jantet G, Wendell-Smith CP, Partsch H. Nomenclature of the veins of the lower limbs: an international interdisciplinary consensus statement. J Vasc Surg 2002; 36(2): 416-22.
4. Sleilaty G, Maoula A, Hachem K, et al. Segmental variations of great saphenous vein diameters in a coronary triple vessel disease population. Ann Cardiol Angeiol (Paris) 2007; 56 (5): 241-6.
5. Mozzon L, Venier E, Gonano N, Biasi G. Sur un cas de double cross saphenienne. In: Davy A, Stemmer R, eds. Phlebologie 89. 1989, pp-14-5.
6. Ricci S, Cavezzi A. Echo-anatomy of long saphenous vein in the knee region: proposal for a classification in five anatomical patterns. Phlebology 2002; 16(3): 111-6.
7. Engelhorn C, Engelhorn A, Salles-Cunha S, et al. Relationship between reflux and greater saphenous vein diameter. J Vasc Technol 1997; 21(3): 167-71.
8. Min RJ, Zimmet SE, Isaacs MN, Forrestal MD. Endovenous laser treatment of the incompetent greater saphenous vein. J Vasc Interv Radiol 2001; 12(10): 1167-71.
9. Oguzkurt L. Endovenous laser ablation for the treatment of varicose veins. Diagn Interv Radiol 2012; 18(4): 417-22.
10. Oguzkurt L. Ultrasonographic anatomy of the lower extremity superficial veins. Diagn Interv Radiol 2012; 18(4):423-30.