

Case Report

Primary Malignant Melanoma of Vagina: The Options of Management

Ng BK (✉)¹, Lim PS¹, Ng YL², Kew TY², Abdul Kadir AK¹, Hatta M¹

¹Department of Obstetrics and Gynaecology, ²Department of Radiology, Faculty of Medicine, Universiti Kebangsaan Malaysia Medical Centre, Jalan Yaacob Latif, Bandar Tun Razak, Cheras, 56000 Kuala Lumpur, Malaysia.

Abstract

Primary malignant melanoma of the vagina is rare but aggressive. Various treatment options include surgery and adjuvant therapy have been advocated but the outcome remained unpredictable. Standard treatment protocol is yet to be established. We report a case of 54-year-old, Para 4+1, with malignant melanoma of the vagina. She underwent wide local excision but the surgical margin was not clear of malignant cells, hence adjuvant radiotherapy was given. Combination chemotherapy was initiated subsequently as her disease disseminated. She succumbed later due to septicemic shock. The treatment options for vaginal melanoma were reviewed.

Keywords: Malignant melanoma, vagina, surgery, radiotherapy, prognosis

Correspondence:

Dr. Ng Beng Kwang, Department of Obstetrics and Gynaecology, Faculty of Medicine, Universiti Kebangsaan Malaysia Medical Centre, Jalan Yaacob Latif, Bandar Tun Razak, Cheras, 56000 Kuala Lumpur, Malaysia. Tel: +603-91455949 Fax: +603-91456672 Email: nbk_9955@yahoo.com/nbk9955@ppukm.ukm.edu.my

Date of submission: 5 Sept, 2013

Date of acceptance: 21 Feb, 2014

Introduction

Primary malignant melanoma of the vagina is rare. Biologically, this tumor is known to be aggressive. The reported incidence was <10% of all melanoma and <5% for cancer of female urogenital tract (1). It affects mostly post-menopausal women and the median age upon diagnosis is at sixth decades of life (2,3,4). The overall 5 years survival rate was poor between 20-27% (3,5). Various treatment options include surgery and adjuvant therapy have been advocated but the outcome remained unpredictable. Standard treatment protocol is yet to be established (6,7). We report a case of recurrent primary malignant melanoma of the vagina. The treatment options were reviewed.

Case Report

A 54-year-old, Para 4+1, post menopausal for four years was not on hormone replacement therapy. She first presented with vaginal growth and abnormal vaginal discharge for 6 months duration associated

with pruritus vulvae. She had no remarkable medical or surgical history except dyslipidaemia. There was no significant family history of gynaecological malignancy.

Upon examination, there was a raised, pigmented growth measuring 30 x 20 mm located at the upper third of anterior vaginal wall. There was no ulceration or bleeding. No palpable inguinal or pelvic lymph node. Other examination was unremarkable.

She underwent wide local excision of the vaginal lesion. The histopathological examination (HPE) showed malignant cell infiltration arranged in nests, islands and sheets. The malignant cells were large pleomorphic with hyperchromatic nuclei and containing large amount of dark pigment (melanin) in the cytoplasm. These cells stained positive with S100, HMB45 and Melan A but CK was negative (Fig. 1). The final diagnosis was malignant vaginal melanoma. Unfortunately, the surgical margin was not clear of malignant cells.

She defaulted follow-up and presented six months later with vaginal mass and vaginal bleeding. She was then given external beam radiotherapy for three fractions in a week in view of persistent per vaginal bleeding as she refused any additional surgical intervention.

One month following radiotherapy, her MRI pelvis (Fig. 2) showed local recurrence with presence of well-circumscribed vaginal mass. Unfortunately, the disease also progressed systemically to the lung. She received six cycles of combination chemotherapy-CVD regime (Cisplatin, Vinblastine and Dacarbazine).

Despite multimodality therapy, her disease progressed to involve the lung, liver, subcutaneous, peritoneal and lymph nodes. She succumbed two months later due to infected chemoport with septicemic shock.

Discussion

Primary malignant melanoma of vagina is a rare entity. The most common presenting symptom is vaginal bleeding (3). Other presentations include palpable vaginal mass, pain, vaginal discharge and itching (8). The lesions commonly found at lower third of vagina in up to 65% of patients (3). In this review, Das et al. reported several unusual sites of primary malignant melanoma, which include cervix, ovary, urethra, rectum, nasal cavity, tongue, breast, tonsillar fossa and cerebral cortex (9). Our patient presented with a mass situated at the upper third of vagina associated with itchiness and abnormal vaginal bleeding.

Various treatment approaches have been attempted however till date there is still lacking of proper guideline or standard treatment protocol. Surgical options ranged from simple WLE to more radical approach such as total vaginectomy and pelvic exenteration.

The role of lymph node dissection remained debatable. Lymphadenectomy is not routinely performed, as the risk of lymph nodes metastasis is relatively low (6). Siu et al. reported a case of metastatic lymph nodes diagnosed by laparoscopic ultrasound and concluded

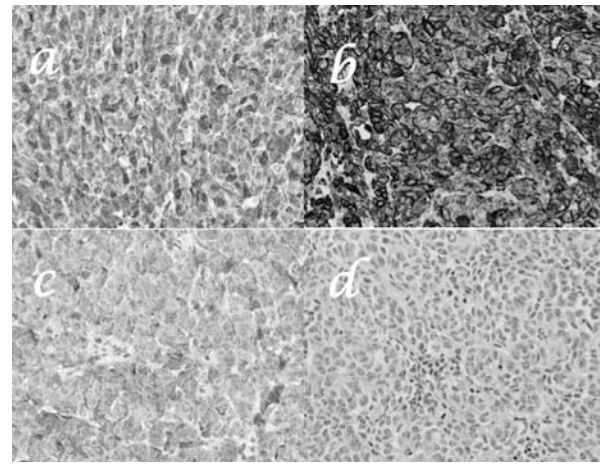


Figure 1: Immunohistochemical studies for the vaginal tumour showed positive staining with a) S100, b) HMB45, c) Melan-A but d) negative for CK

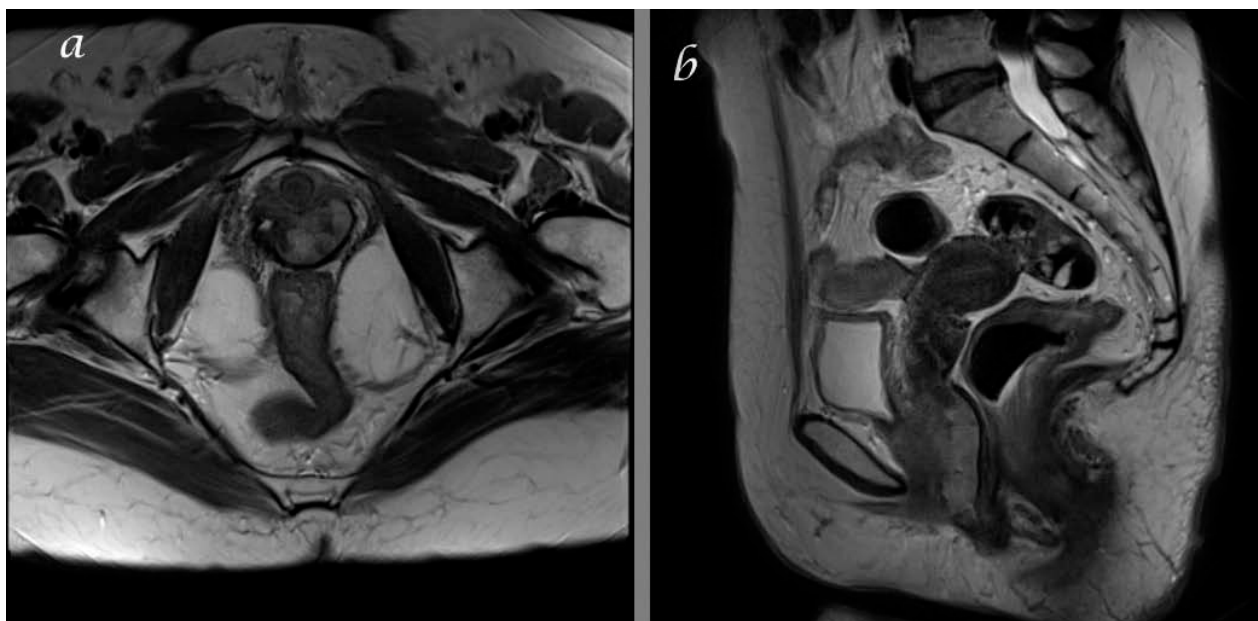


Figure 2: T2 weighted MR image in axial (a) and sagittal (b) views showing a well-circumscribed vaginal wall mass

that it is essential to exclude lymphatic metastasis before radical surgery (10). However, Gungor et al. was not able to demonstrate any lymph node metastasis in all four patients with vaginal melanoma following lymph node resection (8). In view of higher morbidity and mortality of lymph node resection, sentinel node biopsy is gaining popularity. Preoperative lymphoscintigraphy, with its high sensitivity up to 99%, aids in the identification of sentinel lymph node (11). The incidence of nodal recurrence following a false-negative lymphatic mapping and sentinel node biopsy in patients with tumor-negative sentinel nodes is low at 1.3% (11). Phan et al. suggested that sentinel lymph node biopsy should be considered in melanoma with Breslow depth of $\geq 0.76\text{mm}$ (12).

Radiotherapy appeared to be as effective as surgery (2). It may be used as primary therapy when the tumour is surgically non-resectable or medically unfit. Radiotherapy after WLE is associated with lower local recurrence rate and increased survival (3,4).

The role of chemotherapy and immunotherapy in the management of vaginal melanoma has not been fully established although some reports showed promising result (13). Combination chemotherapy such as Dartmouth regime (Dacarbazine, Carmustine, Cisplatin and Tamoxifen), BOLD (Bleomycin, Vincristine, Lomustine and Dacarbazine) and CVD regime (Cisplatin, Vinblastine and Dacarbazine) are frequently used. Lens and Eisen failed to demonstrate any significant benefit in survival between combination therapy and Dacarbazine alone (14). However, the use of combination chemotherapy may still be justified especially in the context of metastatic melanoma.

Buchanan et al. in his review of 67 patients with primary vaginal melanoma, concluded that no significant difference in the outcome between various treatment approaches, namely WLE, radical surgery, radiation therapy or combination therapy (2). In contrast, Frumovitz et al. in his review of 37 women, concluded that survival was significantly longer in those treated surgically than those treated non-surgically (3). Similar finding was reported by Miner et al. (6). On the other hand, combination of conservative surgery with radiotherapy has been suggested to prolong metastasis-free period and the overall survival rate (4). Thus, conservative resection of the gross disease would probably be the mainstay of treatment options for a better clinical outcome (6). Nevertheless, pelvic exenteration shall be reserved for cases of large tumour bulk whereby WLE is not feasible.

One of the factors that influence the survival rate is the size of tumour. It was noted that tumour size less than 3cm has a better mean survival compared to those 3cm and beyond (41 vs 12 months, $p < 0.0024$) (2). Another review by Li et al. revealed that tumour size less than 2cm was associated with longer survival rate (27.7 vs 9.7 months) (15). They concluded that surgery was related to an overall improved survival. The general outcome of the disease would be more favorable if the diagnosis was made earlier and managed with combined modality treatment.

Our patient underwent wide local resection. As the tumour size was 3 cm and beyond and the surgical margin was not clear, she was subjected for adjuvant radiotherapy and combination chemotherapy. Unfortunately, despite combined therapy, her disease progressed. As conclusion, though primary malignant vaginal melanoma is rare, its prognosis remains very poor despite multiple treatment modalities.

Acknowledgement

The authors are indebted to the great distribution by the co-authors for the successful of this case report. A special gratitude to Dr Wong Yin Ping, that provides picture of the HPE specimen.

References

1. Piura B. Management of primary melanoma of the female urogenital tract. *Lancet Oncol* 2008; 9(10): 973-81.
2. Buchanan DJ, Schlaerth J, Kurosaki T. Primary vaginal melanoma: thirteen-year disease-free survival after wide local excision and review of recent literature. *Am J Obstet Gynecol* 1998; 178(6): 1177-84.
3. Frumovitz M, Etchepareborda M, Sun CC, et al. Primary malignant melanoma of the vagina. *Obstet Gynecol* 2010; 116(6): 1358-65.
4. Vaysse C, Pautier P, Filleron T, et al. A large retrospective multicenter study of vaginal melanomas: implications for new management. *Melanoma Res* 2013; 23(2): 138-46.
5. An JS, Wu LY, Li N, et al. Clinical analysis of 42 cases of primary malignant melanoma in female genital tract. *Zhonghua Fu Chan Ke Za Zhi* 2007; 42(5): 320-4.

6. Miner TJ, Delgado R, Zeisler J, et al. Primary vaginal melanoma: a critical analysis of therapy. *Ann Surg Oncol* 2004; 11(1): 34-9.
7. Moros ML, Ferrer FP, Mitchell MJ, Romeo JA, Lacruz RL. Primary malignant melanoma of the vagina. Poor response to radical surgery and adjuvant therapy. *Eur J Obstet Gynecol Reprod Biol* 2004; 113(2): 248-50.
8. Gungor T, Altinkaya SO, Ozat M, Bayramoglu H, Mollamahmutoglu L. Primary malignant melanoma of the female genital tract. *Taiwan J Obstet Gynecol* 2009; 48(2): 169-75.
9. Das P, Kumar N, Ahuja A, et al. Primary malignant melanoma at unusual sites: an institutional experience with review of literature. *Melanoma Res* 2010; 20(3): 233-39.
10. Siu SS, Lo KW, Chan AB, Yu MY, Cheung TH. Nodal detection in malignant melanoma of the vagina using laparoscopic ultrasonography. *Gynecol Oncol* 2004; 92(3): 985-8.
11. Vucetić B, Andreja Rogan S, Balenović A, et al. The role of preoperative lymphoscintigraphy in surgery planning for sentinel lymph node biopsy in malignant melanoma. *Wien Klin Wochenschr* 2006; 118(9-10): 286-93.
12. Phan GQ, Messina JL, Sondak VK, Zager JS. Sentinel lymph node biopsy for melanoma: indications and rationale. *Cancer Control* 2009; 16(3): 234-9.
13. Janco JM, Markovic SN, Weaver AL, Cliby WA. Vulvar and vaginal melanoma: case series and review of current management options including neoadjuvant chemotherapy. *Gynecol Oncol* 2013; 129(3): 533-7.
14. Lens MB, Eisen TG. Systemic chemotherapy in the treatment of malignant melanoma. *Expert Opin Pharmacother* 2003; 4(12): 2205-11.
15. Li Y, Li M, Wu Q. Clinical analysis of 25 cases of primary vaginal malignant melanoma. *Zhonghua Fu Chan Ke Za Zhi* 1999; 34(3): 162-4.