

Case Report

Anatomical Description of a Variant Abductor Digiti Minimi Accessorius Muscle and Its Clinical Correlation with Ulnar Neurovascular Entrapment Syndrome

Avinash T (✉), Smita T, Mona S, Vandana M, Rajesh KS, Gayatri R

Department of Anatomy, Vardhman Mahavir Medical College & Safdarjung Hospital, New Delhi-110029, India.

Abstract

Variations of the abductor digiti minimi muscle are a rare occurrence as compared to anomalous thenar musculature. Surgico-anatomical basis of such accessory muscular slips should be discussed in detail. This case report presents a rare bilateral existence of accessory slips of abductor digiti minimi originating from the antebrachial fascia and flexor retinaculum in a male cadaver. Hypertrophy of these muscular heads can be occult etiologies in causation of ulnar entrapment neuropathies. Such anomalous muscles can prove to be a boon or bane for an operating surgeon. On one hand, they can be the guiding factor in planning myofascial flaps and on the other; they can cause unwanted iatrogenic complications during antero-medial approach through the wrist tendons. Nevertheless, the presence of accessory bellies in the hypothenar eminence deserve a special mention especially if present bilaterally. The authors have attempted to assign an embryological explanation for the above anomaly and have discussed its possible link with various clinical syndromes.

Keywords: Entrapment, abductor digiti minimi, ulnar nerve, Guyon's canal, accessory

Correspondence:

Avinash Thakur, Department of Anatomy, Vardhman Mahavir Medical College & Safdarjung Hospital, New Delhi-110029, India. Tel: +91-9310203126 Email: thakuravns@gmail.com

Date of submission: 31 Jan, 2014

Date of acceptance: 19 June, 2014

Introduction

Anomalies of hypothenar musculature are relatively infrequent but rare cases have been reported in the past (1,2). Supernumerary slips of abductor digiti minimi (ADM) have been defined in the past with various terminologies such as abductor longus digiti quinti (3), musculus flexor digiti minimi accessorius (4) and accessorius ad abductorem minimi digiti manus (5). They can arise from the tendons of palmaris longus, flexor carpi radialis, flexor carpi ulnaris, intermuscular septa, flexor retinaculum and rarely from the antebrachial fascia (1,2,3,4,5). This research work reports a rare bilateral existence of accessory ADM arising from the antebrachial fascia with few fibers originating from the flexor retinaculum. Ulnar neuropathy is a rare entity with a wide range of etiologies like ganglion, neoplasm, vascular

anomalies, tendinous entrapments and myxoma. Aberrant slips of abductor digiti minimi (ADM) can seldom be the root cause of ulnar entrapment neuropathies (6,7). In clinical practice, these accessory slips can sometimes be asymptomatic and can be encountered during surgical procedures or can sometimes mimic soft tissue tumors (8).

Case Report

Routine anatomic dissection of the manus of a 68-year-old male cadaver revealed the presence of a rare anomalous head of origin for the abductor digiti minimi (ADM) bilaterally. The usual head of ADM originated from the pisiform bone and its distal attachment was on the medial side of the base of the proximal phalanx of the fifth digit, bilaterally.

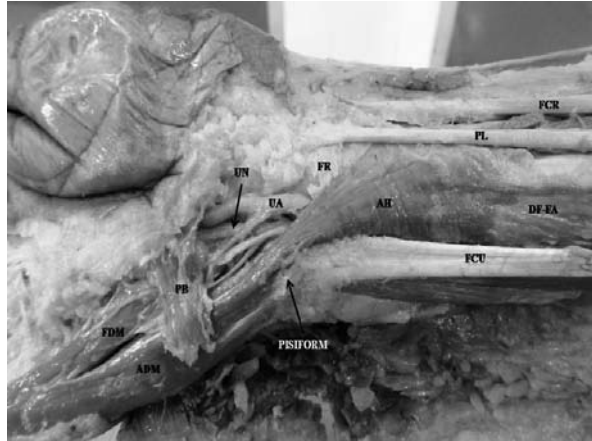


Figure 1: Figure showing right ADM accessorius. (FCR- flexor carpi radialis; PL- Palmaris longus; FR- flexor retinaculum; AH- accessory head of abductor digiti minimi; FCU- flexor carpi ulnaris; DF-FA- deep fascia of forearm; UA- ulnar artery; UN- ulnar nerve; ADM- abductor digiti minimi; FDM- flexor digiti minimi; PB- Palmaris brevis)

On the right side, an accessory head of the ADM (ADM accessorius) was arising from the ante-brachial fascia of the lower third of the forearm (Fig. 1). Few of the fibers of this accessory muscle also took origin from the flexor retinaculum. This triangular ADM accessorius passed obliquely to the ulnar side of the wrist and traversed through the Guyon's canal to form a common fused pennate with the normal head of ADM. Few of its fibers also inserted on the pisiform bone. ADM accessorius originated 3.2 cm superior to the proximal border of the flexor retinaculum and was 4.6 cm in length and 2.4 cm broad at its origin. The ulnar neurovascular bundle coursed deep to this accessory head into the Guyon's canal, the nerve being medial to the artery (Fig. 2). ADM accessorius was related medially to the flexor carpi ulnaris tendon and laterally to the flexor pollicis longus tendon. This accessory head was lying superficial to the flexor digitorum superficialis. It was innervated by the main trunk of the ulnar nerve. Its arterial supply was derived from the ulnar artery just proximal to the flexor retinaculum.

On the left side, a similar anomalous ADM accessorius originating from the ante-brachial fascia and flexor retinaculum (Fig. 3). It had similar relations as its counterpart and measured 4.2 cm in length and 2.2 cm in breadth. The ulnar neurovascular bundle traversed a course deep to this accessory muscle and supplying it en-route. Morphology and anatomical disposition of other hypothenar muscles was normal, bilaterally.

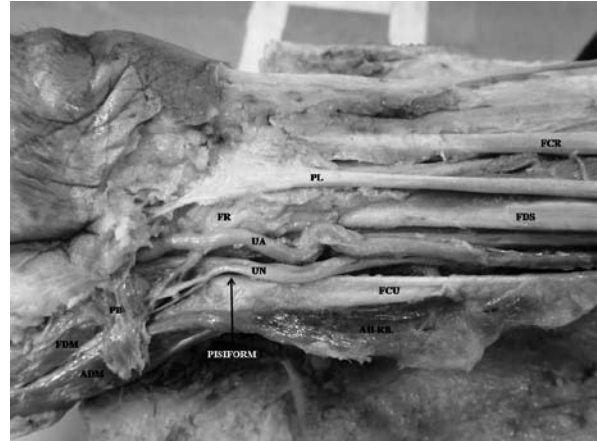


Figure 2: Figure showing neurovascular relations of ADM accessorius. (FCR- flexor carpi radialis; PL- Palmaris longus; FDS- flexor digitorum superficialis; FR- flexor retinaculum; AH-Rfl- reflected accessory head of abductor digiti minimi; FCU- flexor carpi ulnaris; UA- ulnar artery; UN- ulnar nerve; ADM- abductor digiti minimi; FDM- flexor digiti minimi; PB- Palmaris brevis)

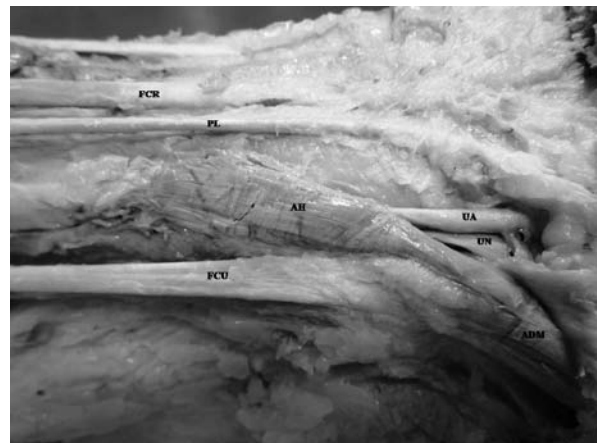


Figure 3: Figure showing left ADM accessorius. (FCR- flexor carpi radialis; PL- Palmaris longus; AH- accessory head of abductor digiti minimi; FCU- flexor carpi ulnaris; UA- ulnar artery; UN- ulnar nerve; ADM- abductor digiti minimi)

Discussion

Variations of the ADM are rare but nevertheless have been reported in the past. The commonly reported ones include anomalies like multiple heads of origin, fusion with the flexor digiti minimi brevis, deep abductor-flexor and even its absence (9). Harvie et al. described the incidence of accessory ADM to be as high as 41% with a greater prevalence in males (10). Murata et al. reported the incidence of accessory

ADM with single slips (17%), double slips (80%) and triple slips (3%) (11).

Madhavi and Holla stated that the coexistence of multiple accessory hypothenar muscles is due to their common muscular phylogeny from a single muscle mass (12). The trilaminar theory of hypothenar muscles describes the ADM to be a marginal part of dorsal musculature of hand which has later extended its origin to the ventral aspect (13). It was stated that ADM and flexor digiti minimi are a part of the single muscle representing the last dorsal interosseous (13). ADM has been considered as inner portion of Palmaris longus (13). McMurrich described the developmental existence of flexor digitorum superficialis and suggested that all the hypothenar muscles were its part (14). ADM is one of the earliest muscles to develop in the region of the hypothenar eminence. The growth of its fibers is influenced by the developing ulnar nerve and its arborization. Accessory slips of ADM can be the consequence of variant ulnar developmental patterns (13).

In the present case, the close relation of ADM accessorius to the ulnar neurovascular structures could possibly be responsible for compression neuropathies. The position and bulk of the accessory muscle belly will be deciding factors in aggravating the symptoms such as par aesthesia, paresis, clawing and atrophy (15). Furthermore, muscular spasms release anoxic substances due to anaerobic metabolism and can cause neural irritation and degeneration (16). A rare consequence of ulnar artery entrapment caused by ADM accessorius can be claudicating pain which can mimic peripheral vascular disorders (17). Therefore, vasculopathies involving ulnar artery may result from the ADM accessorius because of its close relation to the ulnar vessels. Hypothenar hammer syndrome is known to be caused by vascular trauma in the hypothenar region, but may also be related to hypertrophied ADM accessorius (18). Intramuscular myxomas usually occur as isolated lesions and are associated with Mazabraud's or McCune-Albright syndrome (19, 20). Myxomas have been described to occur in the hypothenar muscles and hence ADM accessorius should be borne in mind as an occult site for such myxomas (21).

Abductor digiti minimi rotational flaps have been recently used for soft tissue coverage of the ulnar aspect of the hand and wrist (22). ADM accessorius originating from the fascia and retinaculum as seen in present case may prove to be an excellent alternative for reconstructive surgeries as a vascular pedicle can easily be lifted using the branch from the underlying ulnar artery.

Conclusion

Muscular variations as described in the present report having close relation to important neurovascular structures can become symptomatic due to their hypertrophy. Such accessory slips can also be easily harvested for flap reconstructions. Hence, detailed knowledge of such rare variations become imperative for a better clinical approach.

References

1. Curry B, Kuz J. A new variation of abductor digiti minimi accessorius. *J Hand Surg* 2000; 25(3): 585-7.
2. Soldado-Carrera F, Vilar-Coromina N, Rodriguez-Baeza A. An accessory belly of the abductor digiti minimi muscle: a case report and embryologic aspects. *Surg Radiol Anat* 2000; 22(1): 51-4.
3. Furnas DW. Muscle-tendon variations in the flexor compartment of the wrist. *Plast Reconstr Surg* 1965; 36(3): 320-4.
4. Salgeback S. Ulnar tunnel syndrome caused by anomalous muscles. Case report. *Scand J Plast Reconstr Surg* 1977; 11(3): 255-8.
5. Bergman RA, Thompson SA, Afifi AK. *Catalog of human variation*. Baltimore and Munich: Urban & Schwarzenberg, 1984, pp 41-4.
6. Sheppard JE, Prebble TB, Rahn K. Ulnar neuropathy caused by an accessory abductor digiti minimi muscle. *Wis Med J* 1991; 90(11): 628-31.
7. Netscher D, Cohen V. Ulnar nerve compression at the wrist secondary to anomalous muscles: a patient with a variant of abductor digiti minimi. *Ann Plast Surg* 1997; 39(6): 647-51.
8. Simodynes EE, Cochran RM. Anomalous muscles in the hand and wrist--report of three cases. *J Hand Surg Am* 1981; 6(6): 553-4.
9. Georgiev GP, Jeleu L, Surchev L. Undescribed variant muscle--"deep abductor-flexor" of the little finger, in relation to ulnar nerve compression at the wrist. *Ann Anat* 2007; 189(3): 276-82.
10. Harvie P, Patel N, Ostlere SJ. Ulnar nerve compression at Guyon's canal by an anomalous

- abductor digiti minimi muscle: the role of ultrasound in clinical diagnosis. *Hand Surg* 2003; 8(2): 271-5.
11. Murata K, Tamai M, Gupta A. Anatomic study of variations of hypothenar muscles and arborization patterns of the ulnar nerve in the hand. *J Hand Surg Am* 2004; 29(3): 500-9.
 12. Madhavi C, Holla SJ. Anomalous flexor digiti minimi brevis in Guyon's canal. *Clin Anat* 2003; 16(4): 340-3.
 13. Frazer JE. The derivation of the Human Hypothenar Muscles. *J Anat Physiol* 1908; 42(Pt3): 326-34.
 14. McMurrich P. Phylogeny of the Palmar Musculature. *Am J Anat* 1903; 2(4): 463-500.
 15. Gordon L, Ritland GD. Nerve entrapment syndromes. *Conn Med* 1974; 38(3): 97-102.
 16. Basbaum AI. Distinct neurochemical features of acute and persistent pain. *Proc Natl Acad Sci USA* 1999; 96(14): 7739-43.
 17. Pritchard MH, Pugh N, Wright I, Brownlee M. A vascular basis for repetitive strain injury. *Rheumatology (Oxford)* 1999; 38(7): 636-9.
 18. Ablett CT, Hackett LA. Hypothenar hammer syndrome: case reports and brief review. *Clin Med Res* 2008; 6(1): 3-8.
 19. Logel RJ. Recurrent intramuscular myxoma associated with Albright's syndrome. *J Bone Joint Surg Am* 1976; 58(4): 565-8.
 20. Szendroi M, Rahoty P, Antal I, Kiss J. Fibrous dysplasia associated with intramuscular myxoma (Mazabraud's syndrome): a long-term follow-up of three cases. *J Cancer Res Clin Oncol* 1998; 124(7): 401-6.
 21. Abu Hassan FO, Shomaf M. Intramuscular myxoma of the hypothenar muscles. *Strategies Trauma Limb Reconstr* 2009; 4(2): 103-6.
 22. Stang F, Siemers F, von Wild T, Weyers I, Mailänder P, Stollwerck P. Abductor digiti minimi muscle flap for defect coverage of the hand. *Oper Orthop Traumatol* 2013; 25(4): 372-80.