

## Case Report

# Tube-Cornea Touch Following an Ahmed Valve Implantation in a Patient with Congenital Rubella Syndrome: A Case Report

Edwin Ooi IL, Safinaz MK, Ropilah AR

Department of Ophthalmology, Faculty of Medicine, Universiti Kebangsaan Malaysia Medical Centre, Jalan Yaacob Latiff, Bandar Tun Razak, 56000 Cheras, Kuala Lumpur, Malaysia.

### Abstract

This was a 28-year-old mentally-challenged girl with underlying congenital Rubella syndrome. She was bilaterally aphakic after congenital cataract surgery. She then developed bilateral aphakic glaucoma and had to undergo multiple glaucoma filtering surgeries. The most recent procedure she had undergone for her left eye was a second Ahmed valve implantation with an overlying sclera patch. Postoperatively, intraocular pressure was well controlled. However, nine months later, slit lamp examination revealed the tube was adherent to the overlying cornea with surrounding deep and superficial cornea vascularization. Siedel test was negative and intraocular pressure was normal. Subsequently the tube was removed but the plate was left in situ.

**Keywords:** Rubella syndrome, aphakia, glaucoma, glaucoma drainage implants, corneal opacity

### Correspondence:

Edwin Ooi Inn Loon, Department of Ophthalmology, Faculty of Medicine, Universiti Kebangsaan Malaysia Medical Centre, Jalan Yaacob Latiff, Bandar Tun Razak, 56000 Cheras, Kuala Lumpur, Malaysia. Tel: +60125187909 Fax: +60391456673 Email: innloon80@yahoo.com

Date of submission: 26 Mar, 2014

Date of acceptance: 13 Aug, 2014

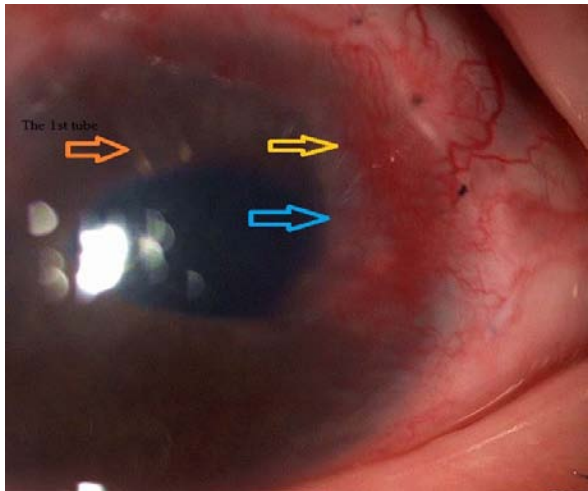
### Introduction

Glaucoma drainage devices provide an alternative treatment in the complicated or refractory glaucoma that does not respond to medical therapy, laser treatment and glaucoma filtering operations (1). The glaucoma drainage device implants consist of a tube that redirects aqueous humour to an end plate (or explant) bypassing the trabecular meshwork (2). They may be further divided into valved and non-valved implants (2). The Ahmed Glaucoma Valve implant is one of the commonly used valved glaucoma drainage device (2). Despite Ahmed valve success, it has significant complications particularly in the anterior segment (3,4,5). Several postoperative complications such as ocular hypotony, bleb encapsulation, tube-related complications may occur following the placement of Ahmed Valve (1,3,4,5). Tube-related complications include tube migration, tube-cornea touch, tube extrusion and tube blockage.

### Case Report

This was a 28-year-old mentally-challenged girl with underlying congenital Rubella syndrome. She was bilaterally aphakic after congenital cataract surgery. She then developed bilateral aphakic glaucoma and had to undergo multiple glaucoma filtering surgeries. The most recent procedure she had undergone for her left eye was a second Ahmed valve implantation with an overlying sclera patch. The surgery was uneventful. Postoperatively, intraocular pressure of the left eye was well controlled, ranging from 10mmHg to 15 mmHg.

However, nine months later, slit lamp examination revealed the tube was adherent to the overlying cornea with full thickness corneal opacity with surrounding deep and superficial cornea vascularization. Siedel test was negative and the intraocular pressure was 12mmHg. Anterior segment photo on presentation was



**Figure 1:** The 2nd tube (yellow arrow) was adherent to the overlying cornea with full thickness cornea opacity (blue arrow).

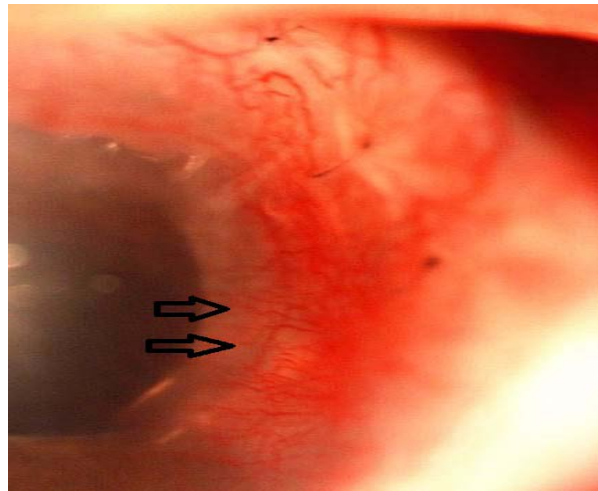
taken (Fig. 1 and Fig. 2). Steroid eye drops were given for the left eye to reduce the inflammatory reaction. The patient was planned for removal of the tube in one month time.

Subsequently, the tube was removed but the plate was left in situ. After the removal of the implant, the corneal vascularization still remained but inflammation of the cornea had reduced (Fig. 3).

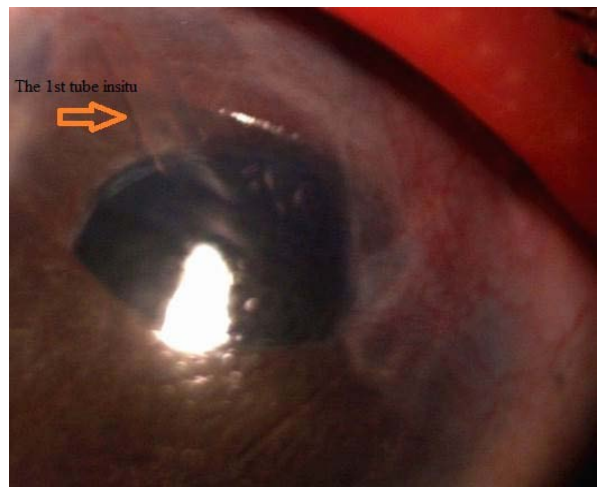
### Discussion

Glaucoma drainage device implants have similar operative and postoperative complications as other glaucoma filtering surgery but they have some unique complications. This case demonstrates a complication of the tube portion of the shunt in a 28-year-old female. It is important to look out for the associated complications of an Ahmed valve tube implant, especially in a case of a mentally-challenged patient who does not voluntarily complain of any eye symptoms. Hence, it is the uttermost importance for us as an ophthalmologist, to try to detect this condition during each clinical examination so that it can be managed in timely manner.

Postoperative tube migration is one of the most common tube-related complication occurring in about 18% up to 35% of patients (1,3,4,5). Mechanism involved might be due to the tube moving more anteriorly and closer to cornea endothelium, following the shrinkage of the sclera and globe after intraocular pressure reduction (5). Tube-cornea touch complication was reported in about 20% of childhood cases (1,6). Local corneal endothelial decompensation



**Figure 2:** Cornea opacity with surrounding deep and superficial cornea vascularization (arrow head).



**Figure 3:** The anterior segment of the left eye following removal of the 2nd tube.

from tube-cornea touch has been hypothesized to potentially prompt a toxic inflammatory reaction in the cornea (7). These events might have led to a slow cornea erosion and corneal scar formation as reported by Al-Torbak and Edward (7). There are a few similar cases being reported as well (7,8,9).

Several factors might have predisposed to the tube migration causing tube-cornea touch resulting in cornea inflammation in this case. Reduction in intraocular pressure in this case might have caused shrinkage of the sclera and globe which prompt to shift the tube anteriorly towards the cornea. As the patient is mentally-challenged, there is a possibility that she has been unintentionally doing vigorous eye rubbing. Vigorous eye rubbing might have shifted the tube forward towards the cornea.

## Conclusion

Despite Ahmed valve success, it is associated with significant complications particularly involving the anterior segment. Several factors might have played a role in the tube migration causing the tube-cornea touch. The tube-cornea touch would have resulted in a local corneal endothelial decompensation. All these events then would have led to a slow corneal inflammation with cornea vascularization as in our patient. Thus, all patients who had glaucoma drainage implants need to be carefully assessed for the tube position in relation to the cornea. A thorough and critical assessment should be made during each clinic visit so that a proper management can be delivered in a timely manner.

## References

1. Englert JA, Freedman SF, Cox TA. The Ahmed valve in refractory pediatric glaucoma. *Am J Ophthalmol* 1999; 127(1): 34-42.
2. Schwartz KS, Lee RK, Gedde SJ. Glaucoma drainage implants: a critical comparison of types. *Curr Opin Ophthalmol* 2006; 17(2): 181-9.
3. Djodeyre MR, Peralta Calvo J, Abelairas Gomez J. Clinical evaluation and risk factors of time to failure of Ahmed glaucoma valve implant in pediatric patients. *Ophthalmology* 2001; 108(3): 614-20.
4. Beck AD, Freeman S, Kammer J, Jin J. Aqueous shunt devices compared with trabeculectomy with Mitomycin-C for children in the first two years of life. *Am J Ophthalmol* 2003; 136(6): 994-1000.
5. Nassiri N, Nouri-Mahdavi K, Coleman AL. Ahmed glaucoma valve in children: A review. *Saudi J Ophthalmol* 2011; 25(4): 317-27.
6. Hill RA, Heuer DK, Baerveldt G, Minckler DS, Martone JF. Molteno implantation for glaucoma in young patients. *Ophthalmology* 1991; 98(7): 1042-6.
7. Al-Torbak A, Edward DP. Transcorneal tube erosion of an Ahmed valve implant in a child. *Arch Ophthalmol* 2001; 119(10): 1558-9.
8. Al-Shahwan S. Transcorneal tube erosion of an Ahmed valve implant in an adult. *Middle East Afr J Ophthalmol* 2010; 17(4): 377-8.
9. Heuer DK, Budenz D, Coleman A. Aqueous shunt tube erosion. *J Glaucoma* 2001; 10(6): 493-6.