

Original Research Article**Incidence of Third Head of Biceps Brachii in South Indian Population**Raju Sugavasi¹ (✉), Indira Devi B², Madhan Krishna E¹, Hima Sarika K¹, Krishna Veni S¹.¹Department of Anatomy, Fathima Institute of Medical sciences (FIMS), Kadapa-516002, Andhra Pradesh, India.²Department of Anatomy, Rajiv Gandhi Institute of Medical sciences (RIMS), Kadapa-516002, Andhra Pradesh, India.**Abstract**

Additional heads of the biceps brachii muscle of arm have the clinical importance, because they mislead the surgeon in arm surgical procedures. Existence of such variation is one of the reasons for neurovascular compression in the arm region. The present study was conducted to find out the incidence of third head of biceps brachii among 80 samples in South Indian population. The third head of biceps brachii was found in right side in one case which was 13.7 cm in length and arising from antero medial wall of lower part of shaft of humerus. Incidence of the study is 1.25% in South Indians. Occurrence of supernumerary third head of biceps is rare in Indian population.

Keywords: Biceps brachii, coracobrachialis, musculocutaneous nerve, third head, anomaly.**Correspondence:**

Raju Sugavasi, Department of Anatomy, Fathima Institute of Medical sciences (FIMS), Kadapa-516002, Andhra Pradesh, India. Tel: 91 9849501978 Fax: 220200-9701501045-22022 Email: anatraju@yahoo.co.in

Date of submission: 26 June, 2015

Date of acceptance: 27 Oct, 2015

Introduction

Biceps brachii is one of the flexor compartment muscle of upper extremity, which consists of two heads. Long head arising from supra glenoid tubercle and short head from coracoids processes of scapula. Both heads join together distally form a bicipital tendon inserts into the radial tuberosity. Third head of biceps brachii originated from superomedial part of brachialis and inserted to medial to bicipital tendon in 10% of cases (1). Third and additional heads of biceps brachii was recognized in the previous literature. Existence of such variations may take origin from the intertubercular sulcus or shaft of the humerus near the coraco brachialis insertion. Sonntag CF (1923) considered this kind of origin, represents as long head of coraco brachialis remnants (2).

Materials and Methods

In the present study, the incidence of third head of biceps brachii in South Indian population was conducted in upper limbs of 40 adults, human formalin

embalmed cadavers in the department of anatomy Fathima Institute of Medical sciences (FIMS), Kadapa and Rajiv Gandhi Institute of Medical sciences (RIMS), Kadapa, Andhra Pradesh, India. Cadavers were dissected by giving a longitudinal incision on the anterior aspect of arm from acromion process to elbow joint and two horizontal incisions were made both the ends of longitudinal incision. Further dissection was carried out to expose the biceps brachii muscle. Specimens were observed accurately, to find out the morphological variations of the origin, insertion and nerve supply of the biceps brachii muscle. Present study considered only normal upperlimbs and excluded lacerated and fractured specimens.

Results

Out of 40 cadavers (80 specimens) third head of biceps brachii muscle was observed in one cadaver, located unilaterally at right side upper limb (Fig. 1). The third head of biceps brachii in that case was noticed in the anteromedial aspect of the lower part of the humeral shaft. It arises at the level of the insertion of

coracobrachialis muscle and distally merged with the tendon of biceps brachii formed a common tendon. The length of anomalous third head of biceps brachii muscle was 13.7cm and it was innervated by musculocutaneous nerve. Incidence of the present study was 1.25% in South Indian population.

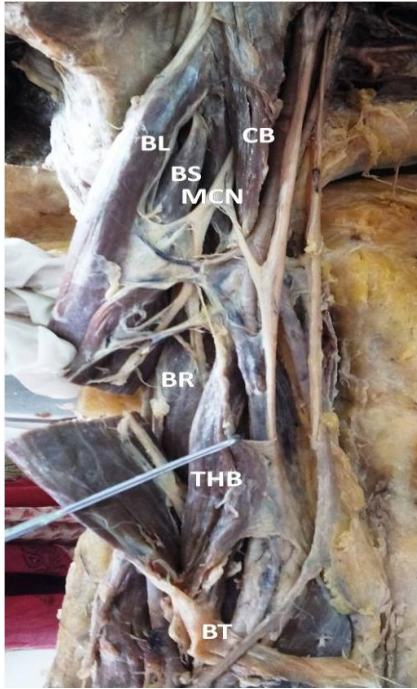


Figure 1: Dissected right arm shows third head of biceps brachii. (BL – biceps long head; BS – biceps short head; CB – coraco brachialis, MCN – musculo cutaneous nerve; BR – brachialis; THB – third head of biceps brachii; BT – biceps tendon).

Discussion

Numerous authors were reported the occurrence of third head of biceps brachii anomaly with a varying incidence in Indian population. Rai et al. reported 3 out of 42 specimens on right side (3). Lokanadhan & Devi reported 2 out of 40 cadavers bilaterally (4). Cheema & Singla reported 3 out of 63 (5). Kumar et al. reported one case of bilateral supernumerary heads of the biceps brachii muscle (6). Kumar et al. reported 1 out of 48 (7).

Present study reported 1.25% incidence in South Indian population. It was less compared to that of previous studies of Soubhagya et al. in Indian population (8).

The third head of biceps brachii in the present study originated from anteromedial aspect of the lower part of the humeral shaft distal to the insertion of coracobrachialis muscle, which was similar to previous reported studies, Kopuz et al. (9) and Abu-Hijleh (10). According to Khaledpour third head of the biceps

brachii muscle was the most common anomaly which was arising from the shaft of the humerus (11). According to Swieter and Carmichael occurrence of a third head arising from the midshaft of humerus is beneficial for forearm pronation and it also improves the power of elbow flexion in relation to size of the variant muscle (12). Testut described embryological reason for happening of third head, as it is a part of the brachialis muscle which innervated by the musculocutaneous nerve, its distal insertion migrated from the ulna to radius (13).

Conclusion

Present variations may be the cause of compression of surrounding neurovascular structures, so anatomical knowledge of anomaly may valuable to orthopedic surgeons. Additional muscle belly sometimes may be mistaken as bone tumors, so this variation may have the diagnostic and surgical importance during upper limb surgeries.

References

1. Susan Standring. Gray's Anatomy: The anatomical basis of clinical practice, 40th ed. Edinburgh: Elsevier Churchill Livingstone, 2008, pp-825.
2. Sonntag CF. On the anatomy, physiology and pathology of the chimpanzee. Proc Zool Soc Lond 1923; 93: 323-429.
3. Rai R, Ranade AV, Prabhu LV, Pai MM, Prakash. Third head of biceps brachii in an Indian population. Singapore Med J 2007; 48: 929-31.
4. Lokanadhan S, Devi SV. Unusual presentation of supernumerary head of biceps brachii in South Indian population. World Journal of Medical Sciences 2011; 6(3): 115-20.
5. Cheema P, Singla R. Low incidence of the third head of biceps brachii in the North Indian population. JCDR 2011; 5(7): 1323-26.
6. Kumar A, Ganesh E, Malarvani T, Singh MK. Bilateral supernumerary heads of biceps brachii. Int J Anat Res 2014; 2(4): 650-52.
7. Kumar H, Das S, Rath G. An anatomical insight into the third head of biceps brachii muscle. Bratisl Lek Listy 2008; 109(2): 76-8.

8. Nayak SR, Prabhu LV, Sivanandan R. Third head of biceps brachii: a rare occurrence in the Indian population. *Ann Anat* 2006; 188:159-61.
9. Kopuz C, Sancak B, Ozbenli S. On the incidence of third head of biceps brachii in Turkish neonates and adults. *Kaibogaku Zasshi* 1999; 74(3): 301-5.
10. Abu-Hijleh MF. Three-headed biceps brachii muscle associated with duplicated musculocutaneous nerve. *Clin Anat* 2005; 18: 376-9.
11. Khaledpour C. Anomalies of the biceps muscle of the arm. *Anat Anz* 1985; 158: 79-85.
12. Swieter M, Carmichael S. Bilateral three-headed biceps brachii muscles. *Anat Anz*, 1980; 148: 346-9.
13. Testut, L. *Tratado de anatomia humana*. Salvat, Barcelona, 1902. pp-1022.