

## Case Report

# Additional Innervations of Pectoral Muscles by the Intercostobrachial Nerve Associated With Duplication of Medial and Lateral Pectoral Nerves – A Case Report

Shetty P, Nayak SB (✉)

Department of Anatomy, Melaka Manipal Medical College (Manipal Campus), Manipal University, Madhav Nagar, Manipal, 576104 Karnataka State, India.

### Abstract

Variations in the nerves of pectoral region are rare. We observed duplication of medial and lateral pectoral nerves in the left upper extremity of an adult male cadaver. The lateral pectoral nerves entered the pectoralis major muscle above the medial border of the pectoralis minor muscle approximately 2 inches below the clavicle. The medial pectoral nerves pierced the pectoralis minor muscle and entered the pectoralis major muscle approximately 3 and 4 inches below the clavicle. The intercostobrachial nerve, apart from its cutaneous supply in the arm, gave a muscular branch that pierced the pectoralis minor (approximately 4 inches below the clavicle) and entered the pectoralis major muscle. The variations observed were unilateral. Knowledge of variations of these three nerves is of importance to plastic surgeons while raising pectoral flaps and also for other surgeons during breast surgeries and axillary lymph node dissection.

**Keywords:** Pectoral nerve, intercostal nerve, pectoralis muscle, axilla

### Correspondence:

Satheesha Nayak B, Department of Anatomy, Melaka Manipal Medical College (Manipal Campus), Manipal University, Madhav Nagar, Manipal, 576104 Karnataka State, India. Tel: +91 8202922519/+91 9844009059 Fax: +91 8202571905. Email: nayaksathish@gmail.com

Date of submission: 12 Jan, 2015

Date of acceptance: 5 Sep, 2015

### Introduction

Pectoralis major and minor muscles are the chief muscles of the pectoral region. They play an important role in the stabilization of pectoral girdle and contribute to the movements of the arm. Pectoralis major muscle takes origin from 2<sup>nd</sup> to 6<sup>th</sup> costal cartilages, sternum and clavicle. It is inserted to the outer lip of the intertubercular sulcus and supplied by the medial and lateral pectoral nerves. The pectoralis minor muscle takes origin from 3<sup>rd</sup> to 5<sup>th</sup> ribs and gets inserted to the coracoid process of scapula. It is also innervated by the medial and lateral pectoral nerves. Pectoral muscles are known to show variations and their variations have been well documented. In a rare congenital condition called Poland syndrome, the sternal part of the pectoralis major muscle is absent (1,

2). A case of bilateral defect in the pectoralis major muscle associated with the absence of lateral pectoral nerves has been reported by Mosconi and Kamath (3). Presence of sternalis and pectoralis quartus muscle are well documented (4,5).

Chondroepitrochlearis is a muscular slip that arises from the pectoralis major muscle and gets inserted to the medial epicondyle of humerus (6). Though there are many reports on variations of the attachments of pectoral muscles, reports on their variant innervation are scanty. We report a rare variation in the innervation of the pectoral muscles. Precise knowledge of variations of attachments and innervation of these muscles contributes greatly to the success of breast surgeries and plastic surgeries.

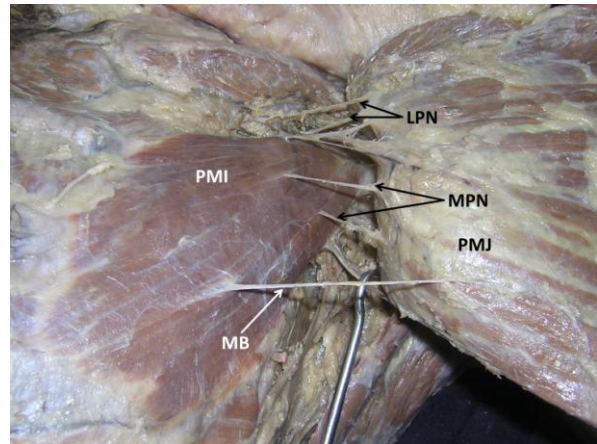
## Case Report

During routine dissection classes for first year medical students, we found additional innervation of the left pectoralis major and minor muscles in an adult male cadaver aged approximately 70 years. The variations observed were unilateral. Both pectoralis major and minor muscles had normal origin and insertions. They were supplied by medial and lateral pectoral nerves. The medial and lateral pectoral nerves were duplicated (Fig. 1). The lateral pectoral nerves entered the pectoralis major muscle above the medial border of the pectoralis minor muscle approximately 2 inches below the clavicle. The medial pectoral nerves pierced the pectoralis minor muscle and entered the pectoralis major muscle approximately 3 and 4 inches below the clavicle. A thick branch of the intercostobrachial nerve pierced the lower part of pectoralis minor muscle (approximately 4 inches below the clavicle) and supplied the pectoralis major muscle (Fig. 1 and 2). This branch came from the intercostobrachial nerve, as soon as it pierced the muscles of the second intercostal space (Fig. 2).

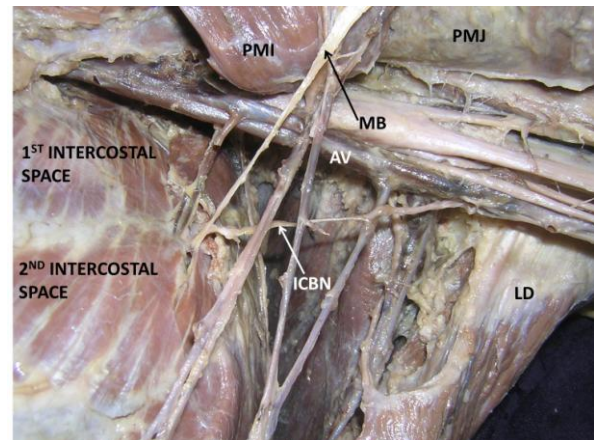
## Discussion

Many reports are available on the variant attachments of the pectoral muscles (1- 6), but reports on variations in their innervation are very rare. We report here, a unique case where there pectoralis major and minor muscles were supplied by a large branch of intercostobrachial nerve. In association with this, the medial and lateral pectoral nerves were also duplicated. Some variations of medial and lateral pectoral nerves have been reported earlier. Rai et al. (7) have reported the presence of accessory lateral pectoral nerves. According to a recent study, medial pectoral nerve was a single trunk in 76% cases and divided into branches in 34% (8). Goel et al. have reported the presence of a single medial pectoral nerve and a duplicated lateral pectoral nerve (9). In a study by Shetty et al. both medial and lateral pectoral nerves arose from the supraclavicular part of the brachial plexus (10).

In the literature, there are reports on variation of intercostobrachial nerve, but its variations are very rare. Loukas et al., have reported an unusual union between the medial pectoral nerve and the intercostobrachial nerve in an 87-year-old female (11). A case of innervation of pectoralis major and minor muscles by intercostobrachial nerve has also been reported (12). Murakami et al. have reported penetration of pectoralis major and minor muscles by the intercostobrachial nerve in two separate cases. In both cases, the nerve supplied the skin of the arm (13).



**Figure 1:** Dissection of the left pectoral region, showing the muscular branch (MB) of intercostobrachial nerve supplying pectoralis major (PMJ) and pectoralis minor (PMI) muscles. Duplication of the medial pectoral nerve (MPN) and lateral pectoral nerve (LPN) can also be seen.



**Figure 2:** Dissection of left axilla showing the muscular branch (MB) of intercostobrachial nerve (ICBN) after reflection of the pectoral muscles. (PMI – pectoralis minor muscle; PMJ – pectoralis major muscle; LD – latissimus dorsi muscle; AV – axillary vein)

The current case is unique in having variations related to all the three nerves found in the pectoral region. Both medial and lateral pectoral nerves showed duplication and the intercostobrachial nerve gave a branch that supplied both pectoralis major and minor muscles. There are no reports on such variations, to date. The upper limb muscles are derived from the lateral plate mesoderm opposite the lower six cervical and upper two thoracic segments. The mesenchyme of this lateral plate mesoderm differentiates into muscle and skeletal elements. While the muscles are formed, the various muscle primordia fuse to form a particular muscle. In certain cases, some primordia disappear as a normal event of development. If there is failure in

degeneration of such primordia, we might find accessory muscles and nerves piercing a muscle/entrapment of nerves (14,15).

Knowledge of this variation is useful for plastic surgeons during raising medial pectoral nerve flaps and also for surgeons operating on the breast. Knowledge of course, distribution and variations of intercostobrachial nerve is quite useful in breast augmentation (16). During radical mastectomy or cosmetic surgeries, denervation of pectoralis major frequently occurs. Hence, thorough knowledge of these nerves is essential (17). In 25% to 60% patients there will be neuropathic pain after breast cancer surgery. This pain is associated with the involvement of intercostobrachial nerve (18). Hence, a thorough knowledge of course, distribution and variations of intercostobrachial nerve is quite useful for general surgeons and plastic surgeons.

### References

- Sharma CM, Kumar S, Meghwani MK, Agrawal RP. Poland syndrome. *Indian J Hum Genet* 2014; 20(1): 82-4.
- Ibrahim A, Ramatu A, Helen A. Poland syndrome a rare congenital anomaly. *Indian J Hum Genet* 2013; 19(3): 349-51.
- Mosconi T, Kamath S. Bilateral asymmetric deficiency of the pectoralis major muscle. *Clin Anat* 2003; 16(4): 346-9.
- Snosek M, Tubbs RS, Loukas M. Sternalis muscle, what every anatomist and clinician should know. *Clin Anat* 2014; 27(6): 866-84.
- Totlis T, Iosifidou R, Pavlidou F, Sofidis G, Natsis K, Bousoulegas A. Complicated axillary lymphadenectomy due to a pectoralis quartus muscle. *Chirurgia (Bucur)* 2012; 107(3): 397-8.
- Samuel VP, Vollala VR. Unusual pectoralis major muscle: the chondroepitrochlearis. *Anat Sci Int* 2008; 83(4): 277-9.
- Rai R, Ranade AV, Prabhu LV, Pai MM, Nayak SR. Accessory lateral pectoral nerves supplying the pectoralis major. *Rom J Morphol Embryol* 2008; 49(4): 577-9.
- Kg P, K S. Anatomical study of pectoral nerves and its implications in surgery. *J Clin Diagn Res* 2014; 8(7): AC01-5.
- Goel S, Rustagi SM, Kumar A, Mehta V, Suri RK. Multiple unilateral variations in medial and lateral cords of brachial plexus and their branches. *Anat Cell Biol* 2014; 47(1): 77-80.
- Shetty P, Nayak SB, Kumar N, Thangarajan R, D'Souza MR. Origin of medial and lateral pectoral nerves from the supraclavicular part of brachial plexus and its clinical importance - a case report. *J Clin Diagn Res* 2014; 8(2): 133-4.
- Loukas M, Grabska J, Tubbs RS, Louis RG Jr. An unusual union of the intercostobrachial nerve and the medial pectoral nerve. *Folia Morphol (Warsz)* 2007; 66(4): 356-9.
- Loukas M, Louis RG Jr, Fogg QA, Hallner B, Gupta AA. An unusual innervation of pectoralis minor and major muscles from a branch of the intercostobrachial nerve. *Clin Anat* 2006; 19(4): 347-9.
- Murakami S, Ohtsuka A, Murakami T. Anterior intercostobrachial nerve penetrating the pectoralis minor or major muscle. *Acta Med Okayama* 2002; 56(5): 267-9.
- Arey LB. *Developmental Anatomy. A Textbook and Laboratory Manual of Embryology*. 6th ed. Philadelphia: WB Saunders Company. 1960, pp-434-5.
- Langman J. *Medical Embryology*. 2nd ed. Baltimore: Williams and Wilkins. 1969, pp-143-6.
- Hwang K, Huan F, Hwang SW, Kim SH, Han SH. The course of the intercostobrachial nerve in the axillary region and as it is related to transaxillary breast augmentation. *Ann Plast Surg* 2014; 72(3): 337-9.
- Macchi V, Tiengo C, Porzionato A, Parenti A, Stecco C, Mazzoleni F, De Caro R. Medial and lateral pectoral nerves: course and branches. *Clin Anat* 2007; 20(2): 157-62.
- Wijayasinghe N, Andersen KG, Kehlet H. Neural blockade for persistent pain after breast cancer surgery. *Reg Anesth Pain Med* 2014; 39(4): 272-8.