

Case Report

An Accessory Head of Abductor Pollicis Longus: Clinical and Anatomical Implications

Bindusar K¹, Ranjeeta H², Susmita S³, Vandana M¹ (✉), Rajesh KS¹

¹Department of Anatomy, Vardhman Mahavir Medical College and Safdarjung Hospital, New Delhi-110029, India.

²Department of Anatomy, Employee's State Insurance Corporation Medical College, Faridabad-121001, Haryana, India.

³Department of Anatomy, Shree Guru Gobind Singh Tricentenary Medical College, Hospital & Research Institute, Budhera, Gurgaon-122505, Haryana, India.

Abstract

An accessory belly of abductor pollicis longus (APL), discovered in the right limb of a cadaver emanating from the main muscle belly was seen to insert onto the tendon of brachioradialis, 3.5 cm proximal to the extensor retinaculum. Measuring 2cm in length, this accessory fleshy belly was seen to bridge over the flexor carpi radialis longus and insert onto the brachioradialis tendon extending for 2 cm along its length. The tendon of APL was inserted by dividing into a superficial and a deep tendon. Such anomalies may be important during surgeries of the hand and especially during reconstruction surgeries involving the APL. The insertion of the accessory belly of APL on the brachioradialis may connote sharing of tendon by two muscles and may have impact on the dynamics of thumb movement when there is simultaneous contraction of both the muscles.

Keywords: Abductor pollicis longus, attachment, De Quervain disease, dissection, tendon

Correspondence:

Vandana Mehta, Department of Anatomy, Vardhman Mahavir Medical College and Safdarjung Hospital, 110029 New Delhi, India. Tel: +91-9910061399 Email: drvandanamehta@gmail.com

Date of submission: 11 May, 2016

Date of acceptance: 29 Sept, 2016

Introduction

The thumb plays a major role in the movements of the hand, and so its muscles are of unique importance. Knowledge of the variations in the muscles helps in planning surgeries in the forearm and the hand and may prevent unwanted damage during such surgeries. The abductor pollicis longus, one of the abductors of the thumb arises from the upper part of the ulna, the interosseous membrane and the radius and gets inserted onto the base of the first metacarpal bone. However anomalous origin and insertion of the muscle may warrant a change in the plan of surgical steps or may require extra care. We report one such anomaly of the abductor pollicis longus.

Case Report

The current case study reports an incidental discovery of an accessory belly of APL during the course of undergraduate training program. Dissection of the right upper extremity in a 50 year old male cadaver revealed an anomalous belly emanating from the muscle belly of APL before the formation of its tendon. This accessory belly was observed to be fleshy throughout its extent and measured 2cm in length (Fig. 1). Furthermore it was seen to merge with the tendon of Brachioradialis, 3.5 cm proximal to the extensor retinaculum. The extent of attachment of this accessory belly of APL to the brachioradialis was 2cm (Fig. 2). However no intermingling of fibres of the APL and brachioradialis

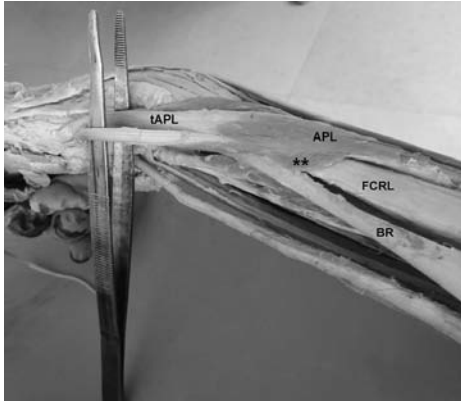


Figure 1: Right forearm (lateral aspect) showing: APL- abductor pollicis longus muscle; FCRL – flexor carpi radialis longus tendon; BR – brachioradialis tendon; tAPL – tendon of abductor pollicis longus; ** - accessory belly of abductor pollicis longus muscle.

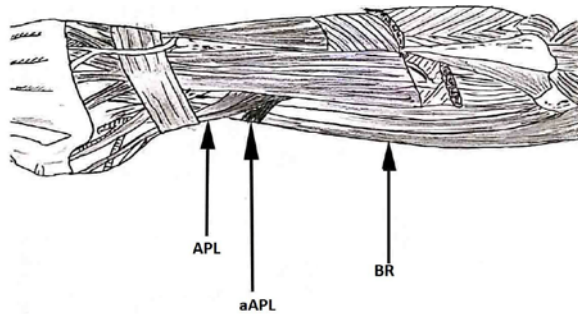


Figure 2: Diagrammatic representation showing attachment of the accessory belly of APL. APL- abductor pollicis longus muscle. aAPL- accessory belly of abductor pollicis longus. BR- brachioradialis.

was observed. The brachioradialis muscle had its normal origin and insertion. The tendon of flexor carpi radialis longus was seen deep to the accessory muscle belly. All the other muscles of the extensor compartment showed no divergence from the usual pattern of attachment. The main belly of the abductor pollicis longus was innervated by the posterior interosseous nerve while the accessory belly did not have a separate nerve supply. The tendon of the APL was seen to bifurcate into a superficial and a deep tendon. The superficial tendon was thicker and measured 5.8cm while the deeper tendon measured 5.2cm. The attachment of the tendons was seen on the base of the first metacarpal and the trapezium. The tendons were accompanied by the extensor pollicis brevis underneath the extensor retinaculum as usual.

Discussion

Although numerous studies have reported accessory tendinous attachments of APL, cases of an anomalous

accessory belly emanating from APL and gaining attachment to brachioradialis is infrequently reported in anatomical archives. In the authors opinion this rare insertion of APL into the brachioradialis tendon may affect the dynamics of thumb movement. The accessory belly did not have a separate nerve supply as reported in similar previous findings (1). Variation in the origin as well as insertion of the abductor pollicis longus has been reported by various workers and has been implicated in conditions like De Quervain disease. Rabi et al. has reported accessory digastric APL wherein the two bellies of APL was seen to arise separately - the accessory belly from the radius (1).

The presence of split tendon of the abductor pollicis longus as seen in the present case, though is a commonly reported variation, none the less deserves mention as it has been implicated in its usage as interposition graft material for the treatment of osteoarthritis of the base of the thumb (2). Similar reports of split tendons have been reported by earlier studies and in standard textbooks (3-6). A similar case report of variation of a accessory muscle slip arising from the brachioradialis and converging into multiple tendons has been reported by Nayak et al. in a cadaver of South Indian origin and Fabrizio et al from America (7,8). Our case is different as APL has an additional attachment into brachioradialis. Yuksel et al. has reported the splitting of the muscle belly of APL into two bellies one of which ended in a tendinous insertion onto abductor pollicis brevis, opponens pollicis and flexor pollicis brevis muscles (4). The other tendon had a normal insertion. Coleman et al. has described similar accessory slip from the abductor pollicis longus to the abductor pollicis brevis and reported an incidence of such occurrence to be 22.7% (9). The incidence of additional slips of the tendons of APL has been reported to be 85% by Elena et al., in which they have further mentioned presence of two slips in 8% of their total cases.

Additionally the insertion of a part of the APL onto the brachioradialis may connote sharing of tendon by two muscles in which the tendon of the brachioradialis may be considered, in part, to be a tendon of APL, as the force of contraction will be transmitted to it.

Cihak et al. pointed out that during embryonic life, the tendon of APL differentiates into three strips, out of which the dorsal strip attaches to the first metacarpal, the middle strip inserts on the trapezium and the palmar strip which lies in a distal direction, attaches to the opponens pollicis. As development progresses the opponens pollicis is bounded by a fascial sheath and the tendon of APL loses connection with it and a new connection with abductor pollicis brevis is established

(10). The variations of APL may be explained as persistence of such connection during embryonic life.

From a kinesiological point of view, the abduction of the thumb may be affected when the tendon of brachioradialis is pulled proximally as in flexion in the mid-pronated position. Furthermore such anomaly may be important in reconstruction surgeries in case of traumatic conditions involving APL and brachioradialis where tendon replacement may be required.

Anomalies such as the one found in our case may be kept in consideration whenever a surgery is being performed on the forearm, and more so when it involves the tendons of the muscle. With a limited operating field during forearm surgeries, such knowledge will definitely help avoid confusion in identifying muscles and differentiating them.

Conclusion

A thorough knowledge of the variations of the muscles of the hand is important for clinicians. Variations in the anatomy of abductor pollicis longus need to be kept in mind while dealing with surgical procedures involving the hand or forearm. The present case report attempts to point out one such variation which may be encountered during reconstructive surgeries or while dealing with pathology of the hand.

References

1. Rabi S, Indrasingh I, Koshy S, Holla SJ, Vettivel S, Suganthy J. An accessory digastric abductor pollicis longus muscle: Report of a case. *Eur J Anat* 2006; 10(2): 79-81.
2. Bravo E, Barco R, Bullón A. Anatomic study of the abductor pollicis longus: a source for grafting

material of the hand. *Clin Orthop Relat Res* 2010; 468(5): 1305-9.

3. Mehta V, Arora J, Suri RK, Rath G. A rare quadruplicate arrangement of abductor pollicis longus tendons: anatomical and clinical relevance. *Clinics (Sao Paulo)* 2009; 64(2): 153-5.
4. Yuksel M, Onderoglu S, Arik Z. Case of an abductor pollicis longus muscle: variation or differentiation? *Okajimas Folia Anat Jpn* 1992; 69(4): 169-71.
5. Standring S. *Gray's anatomy - The anatomical basis of clinical practice*. Elsevier, 2016, pp 854.
6. Paul S, Das S. Multiple tendons of abductor pollicis longus muscle: a cadaveric study with clinical implications. *Kathmandu Univ Med J (KUMJ)* 2006; 4(4): 501-2.
7. Nayak SR, Krishnamurthy A, Pai MM, et al. Multiple variations of the extensor tendons of the forearm. *Rom J Morphol Embryol* 2008; 49(1): 97-100.
8. Fabrizio PA, Clemente FR. A variation in the organization of abductor pollicis longus. *Clin Anat* 1996; 9(6): 371-5.
9. Coleman SS, McAfee DK, Anson BJ. The insertion of the abductor pollicis longus muscle; an anatomical study of 175 specimens. *Q Bull Northwest Univ Med Sch* 1953; 27(2): 117-22.
10. Cihak R. Connections of the abductor pollicis longus and brevis in the ontogenesis of the human hand. *Folia Morphol (Praha)* 1972; 20(2): 102-5.