

Case Report

Bilateral Morphological Variation of Abductor Pollicis Longus and Extensor Pollicis Brevis Tendons: A Cadaveric Case Report with Clinical Perspective

Srinivasa RS, Taranikanti V (✉), Mohammed AM

Department of Human and Clinical Anatomy, College of Medicine and Health Sciences, Sultan Qaboos University, PO Box:35, PC:123, Muscat, Oman.

Abstract

Concurrent morphological variations of abductor pollicis longus (APL) and extensor pollicis brevis (EPB) are seldom reported in literature. Extra slips of APL and EPB are clinically significant as they are used to reconstruct the ruptured tendons in the hand. Herein, we report bilateral morphological variations of APB and EPB in a male cadaver. On each side of forearm, APL was divided into two tendinous slips within the first compartment of extensor retinaculum. One of these slips inserted on to the radial side of base of first metacarpal bone close to the insertion of EPB, and the other slip inserted on to both abductor pollicis brevis and opponens pollicis. EPB divided into two tendons slips deep to the extensor retinaculum. These slips were found to be inserted on to the dorsal surface of the base of proximal phalanx while the other inserted on to the radial aspect of the base of first metacarpal bone, close to the insertion of APL tendon. These additional slips are frequently associated with first carpo-metacarpal subluxation and de Quervain's syndrome and may be responsible for the clinical manifestations of these diseases. In addition, knowledge of the morphological variations of APL and EPB can aid orthopaedic and plastic surgeons in performing successful tendon transplants.

Keywords: Abductor pollicis longus, additional slip, extensor pollicis brevis, morphological variation, retinaculum

Correspondence:

Varna Taranikanti. Department of Human and Clinical Anatomy, College of Medicine and Health Sciences, Sultan Qaboos University, Muscat, Oman. Tel: +968 97675735 Fax: +968 24141175 E-mail: varna@squ.edu.om

Date of submission: 27 Dec, 2016

Date of acceptance: 8 Mar, 2017

Introduction

APL and EPB are deep group muscles of extensor compartment of forearm. Tendons of these two muscles pass through the first facial compartment of extensor retinaculum, at the dorsum of the wrist. Among all the contents of the extensor compartment of forearm, these two muscles are known to present variations frequently but concurrent variations are uncommon.

APL proximally takes origin from the posterior surfaces of radius, ulna and interosseous membrane. Typically it is inserted to radial aspect of base of the first metacarpal bone. Its actions are abduction and extension of carpo-metacarpal joint of thumb (1).

Occurrence of additional tendons has been reported and may insert to the trapezium, opponens pollicis, flexor pollicis brevis, abductor pollicis brevis or to the thenar fascia (2). EPB takes origin from the posterior surface of the radius as well as the adjacent interosseous membrane, distal to the APL origin. After passing under the extensor retinaculum, it is inserted distally to the dorsal surface of base of proximal phalanx of the thumb. Its main function includes extension of metacarpo-phalangeal joint of the thumb and along with other muscles it produces abduction of wrist and thumb (1). Complete absence or additional tendons of EPB with variable site of insertions have been reported (3). Both APL and EPB are used as grafting material for hand reconstruction surgeries (4). Anatomic variations involving APL and EPB are

clinically important for plastic and orthopaedic surgeons to prevent inadvertent injuries and successful procedures. Herein, we report a rare case of bilateral morphological variation of APL and EPB and discuss its clinical implications.

Case Report

During regular dissection classes for medial undergraduate students, we noted a rare bilateral morphological variation of APL and EPB in a male embalmed cadaver that has been used for educational and research purpose. In both right and left forearms, APL took origin from the middle third of posterior surface of radius, interosseous membrane and ulna. At the lower end of forearm, it crossed spirally around the tendons of extensor pollicis longus and extensor pollicis brevis. It passed deep to the extensor retinaculum in the first facial compartment, along with the EPB. Within the compartment it divided into two slips. On both sides, one of these slips inserted on to the radial side of the base of first metacarpal bone close to the insertion of EPB, while the other tendon inserted on to both abductor pollicis brevis and opponens pollicis by a flat aponeurosis. On each side, EPB took origin from the posterior surface of radius and interosseous membrane distal to the APL attachment. At the lower end of the forearm, it crossed two extensor tendons (extensor pollicis longus and extensor pollicis brevis). Then, EPB divided into two slips within the first compartment of the extensor retinaculum. On both right and left sides, one of these inserted on to the dorsal surface of base of proximal phalanx; whereas the other slip inserted to the radial aspect of base of first metacarpal bone, close to the insertion of APL tendon (Fig. 1 and 2).

Using Vernier calipers the thickness and width of the main tendon of EPB was measured at the distal end of extensor retinaculum and it was found to be 2mm and 5mm respectively on the left side, and 2mm and 4mm respectively on the right side. In comparison the thickness and width of its lateral slip was 1mm and 1.5mm respectively on the left side, and 0.5mm and 1.5mm on the right side respectively. Its medial slip was found to be 2mm thick and 4mm in width on the left side and 2mm thick and 4.5mm in width on the right side.

The thickness and width of the main tendon of APL was measured and it was found to be 1.5mm and 6.5mm respectively on the left side and 2mm and 5mm respectively on the right side. In comparison the thickness and width of its lateral slip was 1mm and 3mm respectively on the left side, and 1.5mm and 4mm on the right side respectively, whereas the medial

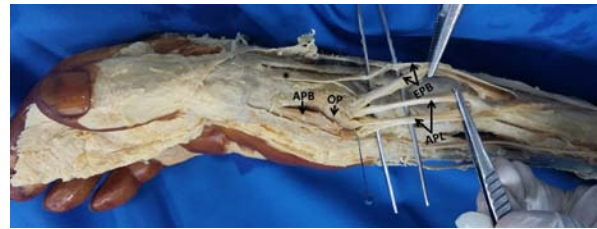


Figure 1: Dissection of right hand showing the insertion of abductor pollicis longus (APL) and extensor pollicis brevis (EPB) tendons. Note the insertion of additional slip of APL to the abductor pollicis brevis (APB) and opponens pollicis (OP). Insertion of additional slip of EPB to the base of first metacarpal bone also seen. Asterisk indicates insertion of EPB tendon to the proximal phalanx.

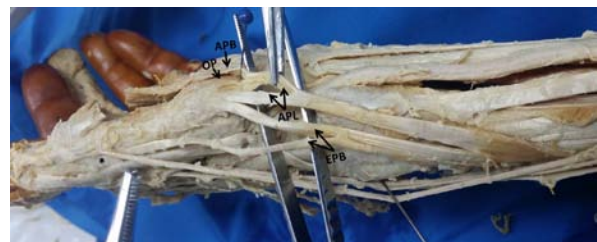


Figure 2: Dissection of left hand showing the insertion of abductor pollicis longus (APL) and extensor pollicis brevis (EPB) tendons. Note the insertion of additional slip of APL to the abductor pollicis brevis (APB) and opponens pollicis (OP). Insertion of additional slip of EPB to the base of first metacarpal bone also seen. Asterisk indicates insertion of EPB tendon to the proximal phalanx.

slip was found to be 0.5mm thick and 1mm in width on the left side, and 1.5mm thick and 4mm in width on the right side. (Fig. 3 and Fig. 4)

Comparing the other extensor tendons (Extensor indicis tendon) in the vicinity at the level of the distal end of extensor retinaculum on both sides, the thickness and width were 1.5mm thick and 4mm wide. Their dimensions were similar to the main tendons of APL and EPB.

Discussion

APB is known to show variations in number of tendons, insertion sites and size of the tendon. Ethnic differences have been observed in these variations. In a study by Roy et al. additional tendons were observed in 74.41% cases (5). The number of additional tendons varies from two to nine. Paul and Das have noted three tendinous slips of APL which were reunited and inserted into first metacarpal bone by a flat aponeurosis (6). Mehta et al. have reported a rare case of quadruplicate arrangement of APL tendons (7). Melling et al. have reported presence of seven APL

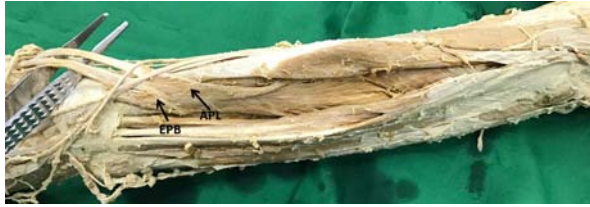

Figure 3: Dissection of left forearm showing the attachments of abductor pollicis longus (APL) and extensor pollicis brevis (EPB).



Figure 4: Dissection of right forearm showing the attachments of abductor pollicis longus (APL) and extensor pollicis brevis (EPB).

tendons (8). Mansur et al. have reported nine tendons (2). Rayan and Mustafa have reported a case of unusual insertion of additional APL tendon into a variant thenar muscle (9). The most common site of insertion of additional tendons was found to be on base of first metacarpal bone followed by trapezium, abductor pollicis brevis, opponens pollicis, and carpo-metacarpal joint (5).

Phylogenetically, a common muscle mass differentiates into APL and EPB. In humans and gorilla, EPB completely separates from the APL and is smaller in size. In chimpanzee, EPB shows insertion to base of first metacarpal and dorsal surface of the base of the proximal phalanx. In gorilla, APL is attached to both radial side of shaft of first metacarpal and trapezium (10). Therefore existence of anomalies involving the APL and EPB are explained based on atavism.

As APL is important in movement and stabilization of thumb, occurrence of supernumerary slips with multiple insertions are of clinical significance. These additional slips are frequently associated with clinical manifestations of first carpo-metacarpal arthritis or subluxation (11). Use of additional slips of APL as a grafting material for ruptured extensor pollicis longus reconstruction with successful functional restoration has been described (12). Further, knowledge of anatomic variants of APL is crucial during decompression of de Quervain's syndrome (13). Additional slips can be an important source of grafting material for treatment of osteoarthritis of the base of

the thumb, ligamentous and tendinous injuries in the hand. Reporting of possible morphological variations of APL may be helpful for orthopaedic and plastic surgeons while performing hand surgeries.

Morphometric evaluation revealed that size of EPB is found to be lesser than that of APL (3). EPB tendon usually inserted to the dorsal surface of base of proximal phalanx. More commonly it has a supplementary insertion to the base of the distal phalanx. Even it joins the extensor pollicis longus tendon by a fasciculus (2). Various authors have reported presence of additional tendons. Usually these tendons are found to be attached to the base of distal phalanx and extensor apparatus at metacarpophalangeal level (9). Rarely attachment of additional tendon to base of metacarpal bone or trapezium has been reported (3). In the present case, additional tendinous slip of EPB was attached to the radial aspect of base of first metacarpal bone along with the APB.

EPB is frequently used to restore hand function. Various authors have described the importance of EPB in reconstructive hand surgeries. Thumb opposition is restored by grafting extensor carpi ulnaris to the EPB (14). Ruptured extensor pollicis longus in rheumatoid arthritis is corrected by grafting it with EPB tendon (4). EPB tendon is transferred into the carpal tunnel to facilitate thumb opposition and is also used to reconstruct ulnar collateral ligament of the first metacarpophalangeal joint (15).

Conclusion

Knowledge of morphological variations involving EPB and APL tendons is clinically important while performing the mobilization of these tendons for hand reconstructive surgery procedures.

References

1. Snell RS. Upper limb. In: Snell RS, ed. *Clinical Anatomy by Regions*. 9th ed. Philadelphia, PA: Lippincott Williams & Wilkins. 2012, pp. 334-433.
2. Mansur DI, Krishnamurthy A, Nayak SR, et al. Multiple tendons of abductor pollicis longus. *Int J Anat Var* 2010; 3: 25-6.
3. Nayak SR, Hussein M, Krishnamurthy A, et al. Variation and clinical significance of extensor pollicis brevis: a study in South Indian cadavers. *Chang Gung Med J* 2009; 32(6): 600-4.

4. Bravo E, Barco R, Bullon A. Anatomic study of the abductor pollicis longus: a source for grafting material of the hand. *Clin Orthop Relat Res* 2010; 468(5): 1305-9.
5. Roy AJ, Roy AN, De C, et al. A cadaveric study of the first dorsal compartment of the wrist and its content tendons: anatomical variations in the Indian population. *J Hand Microsurg* 2012; 4(2): 55-9.
6. Paul S, Das S. Variant abductor pollicis longus muscle: a case report. *Acta Medica (Hradec Kralove)* 2007; 50(3): 213-5.
7. Mehta V, Arora J, Suri RK, Rath G. A rare quadruplicate arrangement of abductor pollicis longus tendons - anatomical and clinical relevance. *Clinics (Sao Paulo)* 2009; 64(2): 153-5.
8. Melling M, Wilde J, Schnallinger M, Schweighart W, Panholzer M. Supernumerary tendons of the abductor pollicis. *Acta Anat (Basel)* 1996; 155(4): 291-4.
9. Rayan GM, Mustafa E. Anomalous abductor pollicis longus insertion in the thenar muscles. *J Hand Surg Am* 1989; 14(3): 550-2.
10. Giles KW. Anatomical variations affecting the surgery of de Quervain's disease. *J Bone Joint Surg Br* 1960; 42-B: 352-5.
11. Schulz CU, Anetzberger H, Pfahler M, Maier M, Refior HJ. The relation between primary osteoarthritis of the trapeziometacarpal joint and supernumerary slips of the abductor pollicis longus tendon. *J Hand Surg Br* 2002; 27(3): 238-41.
12. Bullón A, Bravo E, ZARBASH S, Barco R. Reconstruction after chronic extensor pollicis longus ruptures: a new technique. *Clin Orthop Relat Res* 2007; 462: 93-8.
13. Okada M, Kutz JE. Excision of aberrant abductor pollicis longus tendon slips for decompression of de Quervain's disease. *J Hand Surg Eur* 2011; 36(5): 379-82.
14. Kessler I. Transfer of extensor carpi ulnaris to tendon of extensor pollicis brevis for opponensplasty. *J Bone Joint Surg Am* 1969; 51(7): 1303-8.
15. Fairhurst M, Hansen L. Treatment of "Gamekeeper's Thumb" by reconstruction of the ulnar collateral ligament. *J Hand Surg Br* 2002; 27(6): 542-5.