

Case Report

Colonic Metastasis from an Invasive Lobular Carcinoma of the Breast

Norfaidhi Akram MN (✉), Samuel T, Norly S, Ros'aini P

Department of Surgery, Hospital Pakar Sultanah Fatimah, Jalan Salleh, 84000 Muar, Johor, Malaysia.

Abstract

Breast carcinoma to the colon and rectum is rare type of metastatic spread. We report a case of colonic metastasis from a lobular carcinoma of the breast twelve years after the initial diagnosis. Accurate diagnosis and early treatment of systemic therapy can be done if awareness is increased.

Keywords: Breast metastasis, carcinoma, colon, lobular, neoplasm

Correspondence:

Norfaidhi Akram Mat Nor. Department of Surgery, Hospital Pakar Sultanah Fatimah, Jalan Salleh, 84000 Muar, Johor, Malaysia.
Tel: 00-60-17-6886756 Fax: 00-60-6-9526003 E-mail: norfaidhiakram@gmail.com

Date of submission: 30 Jul, 2017

Date of acceptance: 16 Sept, 2017

Introduction

Regardless of sex in Malaysia, most common cancer is breast cancer (1). The two most common histologic types of breast cancer are invasive ductal and lobular carcinoma. Breast cancers typically metastasize to the lungs, liver and bones. In patients with disseminated disease, few reports of colonic metastasis from breast cancer can be found (2). The risk of developing metastasis is there despite long disease free interval (3). In the present study we report a case of colonic metastasis from a lobular carcinoma of the breast twelve years after the initial diagnosis.

Case Report

A 60-years-old lady was diagnosed with left breast invasive lobular carcinoma 12 years prior to current presentation. She underwent a left modified radical mastectomy with level II axillary clearance, followed by 6 cycles of chemotherapy and 15 cycles of radiotherapy. She also completed 5 years of hormonal therapy (tamoxifen). Four years ago she developed metastasis to both her ovaries. She was then subjected to a total abdominal hysterectomy with bilateral salpingo-oophorectomy and omentectomy. Following that she had another 6 cycles of chemotherapy (Doxetaxel). She had been well until September 2016 when she developed lower abdominal pain. A contrast

enhanced computed tomography scan of the thorax, abdomen and pelvis revealed a long segment wall thickening involving the whole of the large bowel. A colonoscopy examination was done and it showed inflamed mucosa up to 20 cm from the anal verge. The biopsy of the colon revealed metastatic lobular breast carcinoma (Fig. 1). Following she underwent six cycles of CMF (cyclophosphamide, methotrexate, 5-fluorouracil). Currently, she is asymptomatic from the colonic point of view at the moment. Literature review on the management of colonic metastasis from the breast was done and discussed.

Discussion

Among all breast adenocarcinomas, lobular carcinoma accounts for only 8-14%. The metastatic pattern of lobular carcinoma is more towards unusual locations such as gastrointestinal tract, gynaecological organs and peritoneum. A PubMed review revealed a narrowed number of reports of breast cancer with metastatic spread to the colon and rectum (less than 50 cases).

In reported literature, the duration from the diagnosis of breast cancer to presentation of gastrointestinal metastasis ranged from synchronous presentation to 26 years after the initial diagnosis (4). Our patient presented 12 years after the initial diagnosis. The

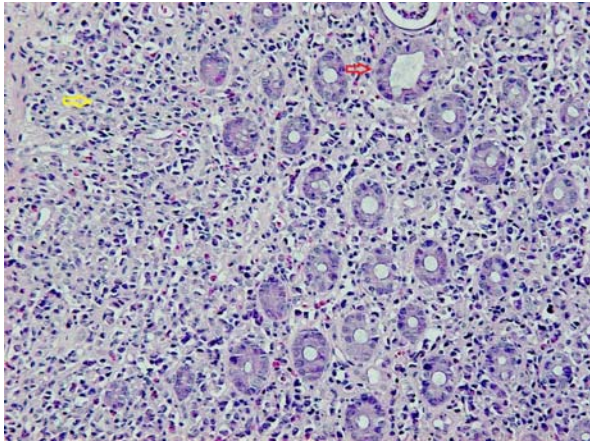


Figure 1: Hematoxylin and eosin stain at 200x magnification showed light microscopy image showing malignant tumour cells dispersed throughout lamina propria of large intestine (yellow arrow), some of which were present in a simple file strands. The image showed fragments of colonic mucosa with no ulcer of dysplasia (red arrow). In further studies, the malignant cells are positive for CK7 and ER (3+, in 90% cells). They are negative for CK20, PR, leucocyte common antigen, TTF-1 and e-cadherin.

clinical presentation is varied and non-specific. It is difficult to differentiate metastatic breast to colon from a primary colon or rectal cancer. This can make the diagnosis difficult and often unexpected. It may also lead to inappropriate management and chemotherapy regime.

There is no consensus in the management of patient with gastrointestinal metastasis of lobular carcinoma, reflecting the generally low level of clinical background in dealing with such conditions. Ciulla et al in 2008 advocated that systemic therapy should be the first option (5). Surgical treatment of the metastasis is considered in cases with obstruction or bleeding (5). Resection of bowel did not significantly improve overall survival of breast cancer patients with gastrointestinal tract metastasis (6). The overall survival of these patients is also poor reflecting the advanced nature of the disease. Our patient is currently asymptomatic from the colonic point of view and no colonic resection is planned for her for the time being.

Conclusion

Gastrointestinal metastases from breast cancer are a rare entity. The presentation could imitate primary colon cancer. Clinical presentation, the availability of chemotherapeutic agents as well as quality of life should be considered before surgical intervention if offered. In lobular breast carcinoma, despite long disease-free interval, the possibility of disease recurrence must always be acknowledged. As the breast cancer survival patients' is rising, we will see an escalating incidence of this extraordinary pattern of metastatic spread of breast cancer.

References

1. Lim GCC, Rampal S, Halimah Y. Cancer Incidence in Peninsular Malaysia 2003-2005. Kuala Lumpur: National Cancer Registry, 2008, pp- 125-7.
2. Koutsomanis D, Renier JF, Ollivier R, Moran A, el-Haite AA. Colonic metastasis of breast carcinoma. *Hepatogastroenterology* 2000; 47(33): 681-2.
3. Yokota T, Kunii Y, Kagami M, et al. Metastatic breast carcinoma masquerading as primary colon cancer. *Am J Gastroenterol* 2000; 95(10): 3014-15.
4. Haberstich R, Tuech JJ, Wilt M, Rodier JF. Anal localization as first manifestation of metastatic ductal breast carcinoma. *Tech Coloproctol* 2005; 9(3): 237-8.
5. Ciulla A, Castronovo G, Tomasello G, et al. Gastric metastases originating from occult breast lobular carcinoma: diagnostic and therapeutic problems. *World J Surg Oncol* 2008; 6: 78.
6. McLemore EC, Pockaj BA, Reynolds C, et al. Breast cancer: presentation and intervention in women with gastrointestinal metastasis and carcinomatosis. *Ann Surg Oncol* 2005; 12(11): 886-94.