

Case Report

Atypical Presentation and Delayed Diagnosis of Herlyn-Werner-Wunderlich Syndrome: A Case Report and Literature Review

Rangasamy A¹ (✉), Rao M², Apana AN³

¹Urogynaecology Unit, Department of Obstetrics & Gynaecology, Hospital Tunku Azizah, 50300 Kuala Lumpur, Malaysia

²Department of Obstetrics & Gynaecology, Hospital Raja Permaisuri Bainun, Jalan Raja Ashman Shah, 30450 Ipoh, Perak, Malaysia

³Faculty of Medicine, Universiti Kuala Lumpur, Royal College of Medicine Perak, 30450 Ipoh, Perak, Malaysia

Abstract

Herlyn-Werner-Wunderlich syndrome (HWWS) is a rare and complex Mullerian duct abnormality that is diagnostically challenging. It is also known as OHVIRA syndrome. The triad of uterine didelphys, obstructed hemivagina and ipsilateral renal anomaly characterises the syndrome. A 25-year-old lady was referred with prolonged foul-smelling vaginal discharge. Her periods were regular with normal flow. A vaginal examination revealed a normal cervix and fullness of left adnexa. A pelvic ultrasound showed a left adnexal mass. Computed tomography imaging of the abdomen and pelvis revealed two uterine cavities with a large cystic lesion at the level of the cervix. This lesion was communicating with the uterine cavity, raising the possibility of obstruction. Only the right kidney was present. A diagnosis of HWWS was made. The patient underwent diagnostic laparoscopy, examination under anaesthesia and excision of the vaginal septum. At follow-up, she remained well at 6 weeks and 3 months. The normal mesonephric duct plays an important role in the formation of the uterus, vagina and the upper urinary tract. HWWS occurs when one of the mesonephric ducts is absent or injured during embryogenesis. Women with HWWS usually present after menarche with varied symptoms, causing delays in diagnosis and treatment. Therefore, having a high suspicion index and awareness of Mullerian duct abnormalities is crucial. The gold standard for the evaluation of HWWS is magnetic resonance imaging. Surgical excision of the septum is the advocated treatment of choice. Prompt intervention lowers complications that impair fertility.

Keywords: Herlyn-Werner-Wunderlich syndrome; Mullerian duct abnormality; OHVIRA; renal agenesis; uterus didelphys

Correspondence:

Aruna Rangasamy. Urogynaecology Unit, Department of Obstetrics & Gynaecology, Hospital Tunku Azizah, 50300 Kuala Lumpur, Malaysia. Tel: +6012 9050601 E-mail: arunagill82@gmail.com

Date of submission: 09 Sept, 2024

Date of acceptance: 29 Nov, 2024

INTRODUCTION

Herlyn-Werner-Wunderlich syndrome (HWWS) is a rare, complex Mullerian duct abnormality. The true incidence is unknown but reported to be 0.1-3.8% (1). The triad of uterine didelphys, obstructed hemivagina and ipsilateral renal anomaly characterises this syndrome. Herlyn-Werner first reported the association between renal agenesis and ipsilateral

blind hemivagina in 1971 (2). Following this in 1976, Wunderlich described the association between right renal agenesis and bicornuate uterus in the presence of an isolated haematocervix (3), giving rise to its eponymous name. Otherwise, this syndrome is also known by the acronym OHVIRA, which stands for Obstructed Hemi-Vagina and Ipsilateral Renal Anomaly. Here we presented a case of a 25-year-old

lady who presented with prolonged vaginal discharge and was subsequently diagnosed to have HWWS.

CASE REPORT

A 25-year-old woman was referred from the local clinic to our centre for ovarian mass to exclude malignancy. Her main presenting complaint was worsening foul-smelling vaginal discharge, which had been present for many years. There were no constitutional symptoms. She had no other medical problems with no family history of malignancy and had been married for 7 years but was unable to conceive. Unfortunately, she never sought treatment and was never investigated for primary subfertility. Her menstrual cycle was regular since menarche at the age of 13. She denied abdominal pain, dyspareunia or dysmenorrhea.

On examination, her vital signs were normal, but she was obese, with a body mass index of 38.8 kg/m². The abdomen was thick but soft and non-tender with no apparent palpable mass. Per speculum examination showed a copious amount of foul-smelling discharge with difficulty to visualise the cervix. High vaginal swab and Pap smear were taken. Vaginal examination revealed a single cervix which felt normal with os closed. The uterus was 8 weeks in size and pushed posteriorly. There was left adnexal fullness with a cystic mass of about 4 x 4 cm. There was no mass palpable on the right adnexa.

A pelvic ultrasound showed an axial uterus with a thin endometrial lining. The right ovary was 3 x 2.1 cm. A left ovarian mass was seen with solid and cystic components measuring 5.4 x 4.3cm. There was no free fluid in Douglas's pouch, and only the right kidney was visible. The impression at the time was left ovarian mass to rule out malignancy with a single right kidney.

Complete blood count and renal function were unremarkable. Tumour markers and Pap smear were normal. A high vaginal swab revealed Group B Streptococcus (GBS). Computed tomography (CT) imaging found no ovarian lesion. However, there was a fundal cleft with two separate uterine cavities suggestive of uterus didelphys. There was a large cystic lesion at the region of the uterine cervix measuring 6.2 x 4.4 x 4.2 cm with communication to the uterine cavity, which raises the possibility of obstruction at the level of the cervix (Fig. 1). There was no obvious extension into the vagina. The presence of a single right kidney was confirmed. The diagnosis was changed to HWWS. Figure 2 shows the schematic representation of HWWS.

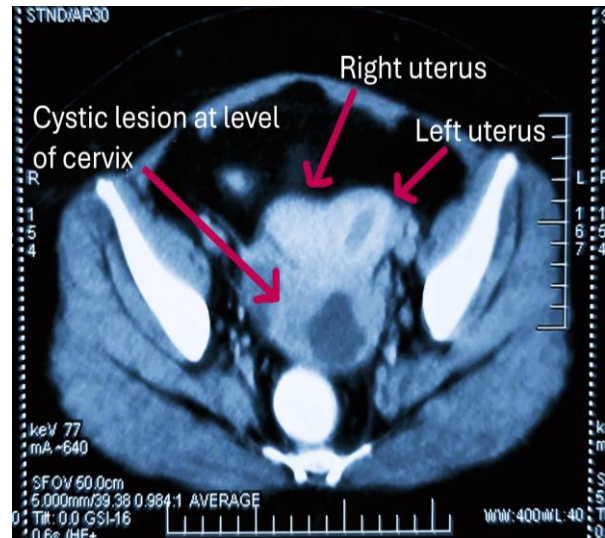


FIGURE 1: CT scan image showing didelphys uterus with collection at the level of uterine cervix communicating with uterine cavity

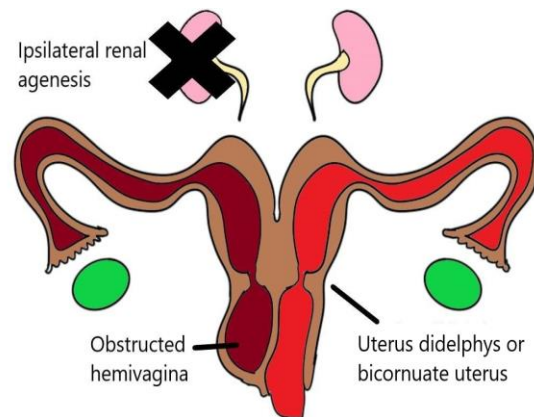


FIGURE 2: Schematic representation of HWWS

The patient was treated with antibiotics for the GBS and underwent diagnostic laparoscopy, examination under anaesthesia, and excision of the vaginal septum. Laparoscopically, two uterine horns were present, indicative of either a didelphys or bicornuate uterus (Fig. 3). Both ovaries and fallopian tubes were normal.

There was no evidence of endometriosis. On speculum examination, the right-sided cervix was seen. There was a bulge to the left of the visualised cervix suggestive of a vaginal septum. It was incised, and a copious amount of foul-smelling pus was released (Fig. 4). The left cervix was challenging to be visualised, but it was felt upon vaginal examination.

The patient made a quick recovery and was discharged home the next day. She was reviewed 6 weeks and 3 months postoperatively and no longer had abnormal vaginal discharge. On examination, both cervixes were seen, and there was no vaginal septum or vaginal stenosis. She was keen to conceive and was referred for preconception counselling.

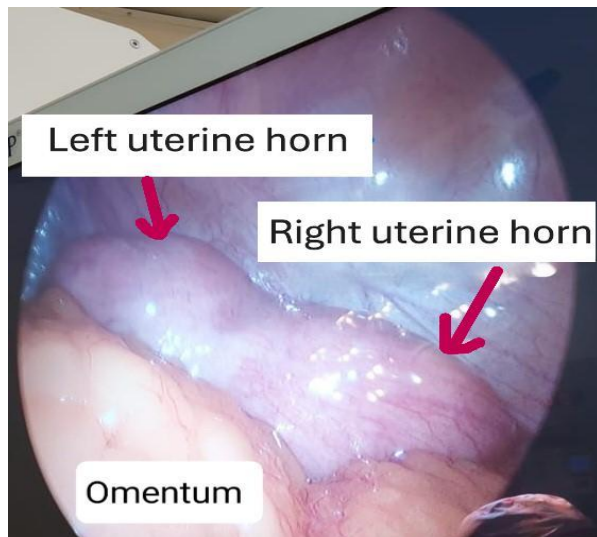


FIGURE 3: Laparoscopy image showing uterus with 2 uterine horns

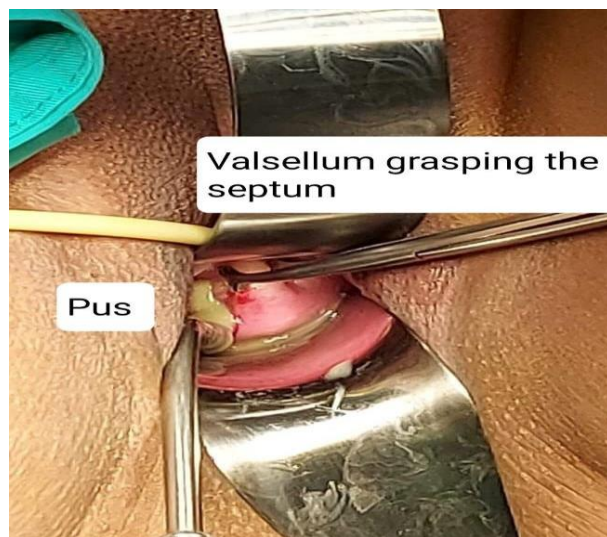

FIGURE 4: Pus draining following resection of septum

DISCUSSION

Embryological Basis of Mullerian Abnormalities

Understanding HWWS requires a basic understanding of embryology. While the classical theory suggests a separate origin for the upper and lower vagina, a more recent theory offers a more comprehensive explanation (4).

According to this theory, the mesonephric ducts play a crucial role in the development of the uterus and vagina. They induce the fusion of the Mullerian ducts and the appropriate resorption of their separating wall. The ureteric bud sprouts from the mesonephric duct and forms the ureter, expanding cranially to form the renal pelvis in the metanephros. Absence or injury to one of the mesonephric ducts can lead to ipsilateral renal agenesis, obstructed hemivagina and uterine abnormalities (4). This insult typically occurs around eight weeks gestation and is more common on the right side (5). Although uterus didelphys is the most commonly associated anomaly, other variations, including bicornuate uterus, are also implicated (6).

Classification of HWWS and Clinical Presentation

As the clinical presentation of HWWS varies based on whether the vaginal septum is entirely or partially obstructed, the latest proposed classification considers this (7). Classification 1 is where the septum completely obstructs the vagina. Patients present soon after menarche with dysmenorrhea and pelvic pain. Acute abdominal pain, fever and vomiting are common presentations (7). They are more likely to have concurrent endometriosis due to the reflux of menstrual blood into the abdominal cavity. Without timely intervention, this can progress into pelvic adhesions and secondary endometriosis that can impair fertility. In Classification 2, the septum partially obstructs the vagina. Therefore, patients tend to present many years after menarche, mainly complaining of mucopurulent discharge and occasionally with a pelvic mass (7), just like our patient.

Due to the vague symptoms and heterogeneity of presentation, diagnosis of HWWS is often delayed or missed. Besides history and clinical examination, imaging plays a crucial role in diagnosing. Pelvic ultrasound is a valuable tool to assess the uterus and adnexa, but it can be challenging in obese patients, as demonstrated. Magnetic resonance imaging (MRI) is the gold standard for pre-operative evaluation of HWWS (8). It can evaluate uterine morphology, detect any communication between the vagina and uterine cavity, and the presence of endometriosis (9). We

performed CT imaging of the abdomen and pelvis as MRI is not readily available at our centre. Although not the gold standard, the CT images were adequate to confirm our diagnosis.

Management of HWWS and Implications

Surgical management remains the mainstay of treatment to alleviate symptoms and prevent complications. Surgery involves excision of the vaginal septum. This can be done as a single-stage procedure except in cases complicated by infection and anatomic distortion, where a 2-stage surgery is recommended (10). Although routine laparoscopy is not essential, it can be done to confirm the diagnosis and look for any complications, such as pelvic inflammatory disease or endometriosis (10). Recently, Cheng et al. (2019) evaluated vaginoscopic incision of the longitudinal vaginal septum using a no-touch technique with good postoperative outcomes (11). It is a good approach for young virgin adolescents with no trauma to the vagina tissue, leaving the hymenal ring intact. Although hysteroscopic or vaginoscopic resection of the vaginal septum are novel techniques used in the management of HWWS, hysteroscopy for the distinction of uterine anomaly in the context of OHVIRA has not been described in the literature. Hemihysterectomy is reserved for cases with cervical atresia where resection of the septum would not relieve the obstructive symptoms (12).

HWWS and Fertility

Fertility is a primary concern for patients. Women with uterus didelphys have the same probability of pregnancy as the general population (13). The incidence of pregnancy in both horns is almost equal (14). The risk of 1st and 2nd-trimester miscarriages was not significantly different from the general population. In a study by Heinonen (2013), 13 out of 21 women with OHVIRA who were surgically treated succeeded in becoming pregnant, whereby 91% of the pregnancies ended with a living infant (12). There was no comparison between pregnancy success rates and different surgical techniques. The common complications encountered are preterm delivery, breech presentation, intrauterine growth retardation and perinatal death. About 80% of pregnancies end up having a Caesarean section (13,15). The risk of pre-eclampsia is higher due to the presence of one kidney (12). Therefore, pregnancies in these patients must be considered high-risk and under consultant-led care to ensure the best outcome for both mother and baby. Aspirin should be considered in these patients once viability is confirmed.

As the patient in the present case report is also keen to conceive, it is crucial that adequate preconception counselling is given about her condition. Furthermore, she has Class 2 obesity, which will compound her risk of pregnancy complications. To improve outcomes, counselling should be provided for weight reduction before embarking on pregnancy.

CONCLUSION

Due to diverse clinical presentations in HWWS, a high index of suspicion is required. Imaging, such as ultrasound and MRI, can aid the diagnosis. Surgical excision of the septum is the recommended treatment. The technique used would depend on the individual case. Timely intervention is of the utmost importance to alleviate symptoms and prevent complications, especially endometriosis and pelvic adhesions, which can impair fertility. Patients should be adequately counselled regarding their chances of pregnancy and the complications they are likely to encounter.

Acknowledgement

We thank Mr. Ganeshwaran Rangasamy, computer and electronics engineer for illustrating the schematic representation of HWWS in Figure 2.

Funding

This work received no funding from any agency.

Ethical approval

Ethical approval was not necessary as this is a case report. Written consent was obtained from the patient.

Declaration of competing interest

None

References

1. Burgis J. Obstructive Müllerian anomalies': Case report, diagnosis, and management. *Am J Obstet Gynecol* 2001; 185(2): 338-44.
2. Herlyn U, Werner H. [Simultaneous occurrence of an open Gartner-duct cyst, a homolateral aplasia of the kidney and a double uterus as a typical syndrome of abnormalities]. *Geburtshilfe Frauenheilkd* 1971; 31(4): 340-7.

3. Wunderlich M. [Unusual form of genital malformation with aplasia of the right kidney]. *Zentralbl Gynakol* 1976; 98(9): 559-62.
4. Acien P, Acien M. Malformations of the female genital tract and embryological bases. *Curr Womens Health Rev* 2013; 3(4): 248-88.
5. Rock JA, Jones HW. The double uterus is associated with an obstructed hemivagina and ipsilateral renal agenesis. *Am J Obstet Gynecol* 1980; 138(3): 339-42.
6. Aswani Y, Varma R, Choudhary P, Gupta RB. Wolffian origin of vagina unfolds the embryopathogenesis of OHVIRA (Obstructed hemivagina and ipsilateral renal anomaly) syndrome and places OHVIRA as a female counterpart of zinner syndrome in males. *Pol J Radiol* 2016; 81: 549-56.
7. Zhu L, Chen N, Tong JL, Wang W, Zhang L, Lang JH. New classification of herlyn-werner-wunderlich syndrome. *Chin Med J (Engl)* 2015; 128(2): 222-5.
8. Khaladkar SM, Kamal V, Kamal A, Kondapavuluri SK. The Herlyn-Werner-Wunderlich syndrome - A case report with radiological review. *Pol J Radiol* 2016; 81: 395-400.
9. Ahmad Z, Goyal A, Das C, Deka D, Sharma R. Herlyn-Werner-Wunderlich syndrome presenting with infertility: Role of MRI in diagnosis. *Indian J Radiol Imaging* 2013; 23(3): 243-6.
10. Smith NA, Laufer MR. Obstructed hemivagina and ipsilateral renal anomaly (OHVIRA) syndrome: Management and follow-up. *Fertil Steril* 2007; 87(4): 918-22.
11. Cheng C, Subedi J, Zhang A, et al. Vaginoscopic Incision of oblique vaginal septum in adolescents with OHVIRA syndrome. *Sci Rep* 2019; 9(1): 20042.
12. Heinonen PK. Pregnancies in women with uterine malformation, treated obstruction of hemivagina and ipsilateral renal agenesis. *Arch Gynecol Obstet* 2013; 287(5): 975-8.
13. Venetis CA, Papadopoulos SP, Campo R, Gordts S, Tarlatzis BC, Grimbizis GF. Clinical implications of congenital uterine anomalies: A meta-analysis of comparative studies. *Reprod Biomed Online* 2014; 29(6): 665-83.
14. Altchek A, Paciuc J. Successful pregnancy following surgery in the obstructed uterus in a uterus didelphys with unilateral distal vaginal agenesis and ipsilateral renal agenesis: Case report and literature review. *J Pediatr Adolesc Gynecol* 2009; 22(5): e159-62.
15. Heinonen PK. Clinical implications of the didelphic uterus: Long-term follow-up of 49 cases. *Eur J Obstet Gynecol Reprod Biol* 2000; 91(2): 183-90.