

Komunikasi Pendek/Short Communication

Vision Status: Presbyopic Patient Undergone Corneal Inlay Procedure (Status Penglihatan: Pesakit Presbiopia Yang Menjalani Prosedur Inlay Kornea)

LINSAY SUNDRAM GNANASUNDRAM, ROKIAH OMAR, BASHIRAH ISHAK & ALOYSIUS JOSEPH LOW

ABSTRACT

This study reports the vision status of a presbyopic patient who has undergone a corneal inlay procedure. The study hopes to provide optometrists more insight on the procedure and the co-management involved in such a patient. The patient, a 48 years-old Chinese woman with presbyopia underwent the corneal inlay procedure three years ago. She had the inlay implanted in the non-dominant eye to aid near vision i.e. her left eye. The pre and post-operative evaluations include distance and near visual acuity, funduscopy, tonometry, Schirmer's test, slit lamp evaluation, corneal topography and corneal pachymetry. Near visual acuity for the left eye improved from N14 to N5 immediately after the procedure. Even after 3 years of post-operative followup, the patient was still able to maintain her near vision. In conclusion, the corneal inlay procedure helped to improve near vision of this presbyopic patient. Optometrist plays a very important role in the co-management of such patients alongside with the ophthalmologist in terms of visual functional assessments pre and post-surgery, counseling of the procedure and managing patients' expectations.

Keywords: Corneal inlay; presbyopia; near vision; functional assessment

ABSTRAK

Kajian ini melaporkan status pesakit presbiopia yang telah menjalani prosedur inlay kornea. Laporan ini diharapkan dapat memberikan optometris gambaran yang lebih jelas mengenai prosedur dan pengurusan pesakit yang terbabit. Pesakit, seorang wanita Cina berumur 48 tahun mengalami presbiopia dan menjalani prosedur inlay kornea tiga tahun lalu. Pesakit telah menjalani implan inlay kornea pada mata bukan dominan untuk membantu penglihatan dekat iaitu pada mata kiri. Penilaian pra dan pasca pembedahan termasuk ketajaman penglihatan jauh dan dekat, fundus, tonometri, ujian Schirmer, pemeriksaan lampu celah, topografi kornea dan pakimetri kornea. Ketajaman penglihatan bagi mata kiri bertambah baik dari N14 ke N5 serta-merta selepas prosedur. Keadaan penglihatan dekat terus kekal selepas 3 tahun menjalani prosedur. Kesimpulannya, prosedur inlay kornea membantu meningkatkan penglihatan dekat pesakit presbiopia. Optometris memainkan peranan yang amat penting dalam pengurusan bersama pesakit dengan oftalmologis dari segi penilaian fungsi visual pra dan pasca pembedahan, kaunseling tentang prosedur inlay kornea dan menguruskan jangkaan pesakit.

Kata kunci: Inlay kornea; presbiopia; penglihatan dekat; penilaian fungsi

INTRODUCTION

Presbyopia is an age-related visual impairment. It is a natural aging process where, our crystalline lens and the ciliary muscles in our eyes lose the capability of flexing to help focus light rays to the retina for clear near vision. It results from the gradual decrease in accommodation expected with age and can have multiple effects on quality of vision and quality of life (Heron et al. 2001). As the amplitude of accommodation diminishes, the range of clear vision may become inadequate for the patient's commonly performed tasks, especially near vision. In our industrialized society, the type of intermediate and near vision requirement includes using the computer, smart phones, reading and paper works (Wilson 1996; Holden et al. 2008). The amplitude of accommodation

reduces slowly up to the age of 40 and declines rapidly and diminishes as presbyopia approached (Heron et al. 2001).

Corneal inlay is a medical device for presbyopic patients to regain clear near vision (Tomita et al. 2012; Low 2011). It is made of Polyvinylidene fluoride (PVDF), a material that is used to make the haptic of intraocular lens. It is biocompatible with the human body. It is an opaque material measuring 3.8 mm diameter and 1.6 mm diameter of opening at the center with 8,400 micro-perforation to allow flow of nutrients and metabolites in cornea layers. It works based on the depth of focus principle (pinhole effect) (Seyeddain et al. 2010). The inlay is implanted by a refractive surgeon on the cornea stromal layer by creating a corneal flap using a femtosecond laser.

MATERIALS AND METHODS

The patient selected was a 48 years-old Chinese female presbyope who was seeking for a solution for her near vision problem other than the conventional methods which are usually reading glasses or bifocal/multifocal lenses if associated with other refractive errors. Her main problems were blur vision at near and did not want to wear reading glasses for her near tasks. She did not like to wear reading glasses because it was inconvenient and cosmetically unappealing. She had never worn glasses for distance and near vision. Optometric and ophthalmologic pre and post-operative examinations were conducted and evaluated on her. These tests included distance and near visual acuity, refraction, tonometry, corneal topography, pachymetry, Schirmer's test slit lamp examination and funduscopy. Written informed consent was obtained from the patient for publication of any accompanying images.

RESULTS

Pre-operative refraction for her right eye was plano with a visual acuity of 6/6 and left eye -0.25 DS with a visual acuity of 6/6. Her unaided near vision was N14 at 35 cm, and her near addition was +1.75 DS with a vision of N5 for both eyes. Intraocular pressure was measured using a non-contact tonometer with a reading of 17 mm Hg for the right eye and 15 mm Hg for the left eye. Corneal topography was done using Orbscan II for both eyes, and no abnormalities were found. Corneal pachymetry (using Orbscan II) was 585 microns for right eye and 588 microns for left eye. The Orbscan II keratometry reading for the right eye was 44.40 DS @ 175, 43.60 DS @ 165 and left eye was 43.60 DS @ 102, 42.60 DS @ 12. Dry eye test was done using Schirmer's test, and the results was 10 mm for right eye and 15 mm for left eye. Fundus examination revealed no abnormalities for both eyes. Patient was found suitable for the corneal inlay procedure to help her regain her near vision. After the optometry and ophthalmology eye examination and consultation, the

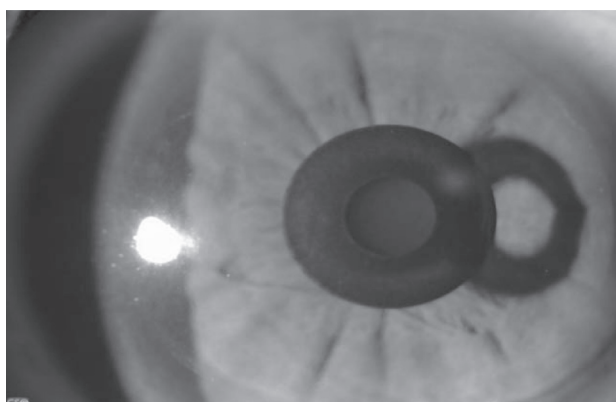


FIGURE 1. Slit lamp image of corneal inlay in patient's eye

patient decided to undergo the procedure in May 2010, cornea inlay (KAMRA™ Inlay) was implanted in the Left Eye (non-dominant eye) to aid for near vision (Fig.1). The left eye with corneal inlay after surgery improves to distance vision of 6/6 and near vision of N5 at 35 cm. The summary of her vision for 3 years post-op are shown on Table 1.

TABLE 1. Uncorrected distance and near visual acuity

Number of Visits	Left eye (OS) Distance Vision	Both Eye (OU) Distance Vision	Both Eye (OU) Near Vision
Pre-Op	6/7.5 ⁺²	6/6	N14
1 year post-op	6/6	6/6	N5
2 years post-op	6/6	6/6	N5
3 years post-op	6/6	6/6	N4

DISCUSSION

The concept of corneal inlay was shown in a graphical representation (Low 2012) in Figure 2. In the representation, it shows that inlay is only implanted on the non-dominant eye, which will improve near vision while the dominant eye is used for distance vision (Wilson 1996). However, with both eyes open simultaneously, the patient will be able to see distance and near without the need to wear glasses for distance and near vision (Low 2012; Tomita et al. 2012).

The pinhole concept of corneal inlay provides the benefit of not needing the aid of reading glasses even though the amplitude of accommodation for patients gradually diminishes after age of 40. The inlay ensures a longer range of depth of focus that helps patient to regain clear near vision. The procedure improves patient's functional near tasks. For the first three to six months, the patient intermittently experienced symptoms of dry eyes (Low 2012), fluctuation and; clarity of vision. However, these did not affect her functional daily task and the slight glare and haloes, which were a part of the healing process in corneal refractive surgery (Holladay 1999). The usage of artificial tears gave a smoother ocular surface, thus making the patient feeling more comfortable and having a clearer vision.

The patient was prescribed preservative-free artificial tears in the morning and evening to ensure smooth cornea surface. When the ocular surface was not dry, the patient experienced good functional near vision. The examination, reassurance and counseling of the optometrist and ophthalmologist during the healing period after the surgery helped the patient tremendously. Sufficient lighting and reading under bright light helped the neural adaptation of the patient.

The corneal inlay is an alternative option for patients who do not like to wear reading glasses, as long the

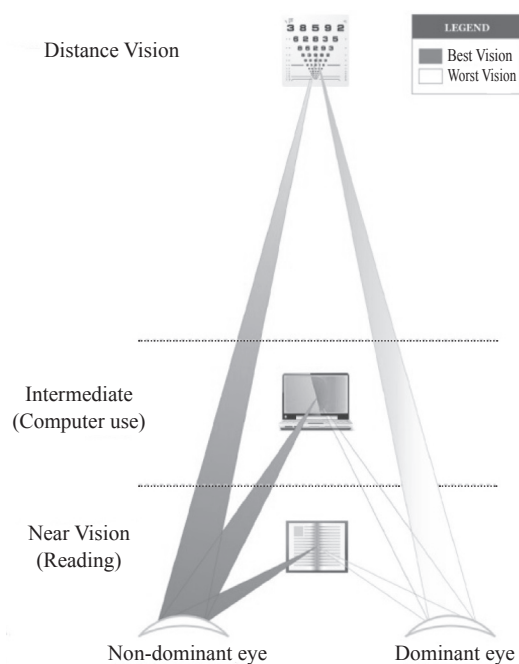


FIGURE 2. Graphical representations corneal inlay procedure
(Source: Vista Laser Eye Centre, Malaysia)

patient's expectation is set right. The clear near vision using through inlay cannot be compared to the clarity of reading glasses. This is because reading glasses serve as magnifiers that amplify the image. On the other hand, Corneal inlay increases the depth of focus with the pinhole principle to allow only focused light to reach the retina. Optometrist plays a role in the pre and post-operative visual functional evaluation and patient counseling on expectations and guiding throughout the healing process. Like any eye treatment, patient's expectation must be set right on possible surgical outcome and healing period to help them prepare for the procedure.

CONCLUSION

Patient was satisfied with functional distance and near vision. Patient can read newspaper and paperwork without reading glasses. In conclusion, the corneal inlay procedure helps improve near vision of this presbyopic patient. Optometrist plays a role in the co-management of the patient alongside with the ophthalmologist in terms of pre and post-surgery visual functional assessments and patient counseling of the procedure and managing expectations.

ACKNOWLEDGEMENT

Vista Eye Specialist, Mutiara Damansara, 47800 Petaling Jaya, Selangor, Malaysia and Universiti Kebangsaan Malaysia for grant HEJIM-INDUSTRI-2013-045

REFERENCES

- Heron, G., Charman, W.N. & Schor, C.M. 2001. Age changes in the interactions between the accommodation and vergence systems. *Optometry & Vision Science* 78(10): 754–762.
- Holden, B.A, Fricke, T.R., Ho, S.M., Wong, R., Schlenker, G., Cronjé, S. & Burnett, A. 2008. Global vision impairment due to uncorrected presbyopia. *Archives of Ophthalmology* 126(12): 1731–1739.
- Holladay, J.T., Dudeja, D.R. & Chang, J. 1999. Functional vision and corneal changes after laser in situ keratomileusis determined by contrast sensitivity, glare testing, and corneal topography. *Journal of Cataract & Refractive Surgery* 3350(99): 663–669.
- Low, A. J. 2011. Presbyopia Correction with the Kamra Inlay: 31–32.
- Low, A.J. 2012. *Mono-vision LASIK or Small-Aperture Corneal Inlay for Treatment of Presbyopia*. Video. American Society of Cataract and Refractive Surgery.
- Seyeddain, O., Riha, W., Hohensinn, M., Nix, G., Dextl, A. K. & Grabner, G. 2010. Refractive surgical correction of presbyopia with the AcuFocus small aperture corneal inlay: two-year follow-up. *Journal of Refractive Surgery* 26(10): 707–715.
- Tomita, M., Kanamori, T., Waring, G. O., Yukawa, S., Yamamoto, T., Sekiya, K., Tsuru, T. 2012. Simultaneous corneal inlay implantation and laser in situ keratomileusis for presbyopia in patients with hyperopia, myopia, or emmetropia: six-month results. *Journal of Cataract & Refractive Surgery* 38(3): 495–506.
- Tomita, M., Kanamori, T., Waring, G. O., Yukawa, S., Yamamoto, T., Sekiya, K., Tsuru, T. 2012. Simultaneous corneal inlay implantation and laser in situ keratomileusis for presbyopia in patients with hyperopia, myopia, or emmetropia: six-month results. *Journal of Cataract & Refractive Surgery* 38(3): 495–506.
- Wilson, W. J. 1996. *Presbyopia: A practice and marketing guide for vision care professional*. Kendall/Hunt Pub. Co. 114.
- Linsay Sundram Gnanasundram
Rokiah Omar
Bashirah Ishak
Optometry & Vision Science Program
Faculty of Health Sciences
Universiti Kebangsaan Malaysia
Jalan Raja Muda Abdul Aziz
50300 Kuala Lumpur, Malaysia.
- Aloysius Joseph Low
Vista Eye Specialist
The Curve, Mutiara Damansara
47800 Petaling Jaya
Selangor, Malaysia
- Corresponding author: Rokiah Omar
Email address: r_omar@ukm.edu.my
Tel: +603-9289 8058; Fax: +603-2691 0488

Received: December 2014
Accepted for publication: November 2015

