

Case Report

Total Pancreatectomy For Diffuse Pancreatic Adenocarcinoma

Azlanudin A, Razman J(✉)

Department of Surgery, Universiti Kebangsaan Malaysia Medical Centre, Jalan Yaacob Latif, Bandar Tun Razak, 56000 Cheras, Kuala Lumpur, Malaysia

Abstract

A 64-year-old lady presented with a brief history of abdominal pain associated with obstructive jaundice. Endoscopic retrograde cholangiopancreatography (ERCP) revealed a short segment stricture with contact bleeding and the brush cytology confirmed presence atypical cells. Ca 19.9 levels were markedly elevated. She was planned for a Whipple's procedure but was instead subjected to a total pancreatectomy based on intraoperative findings of a diffusely hard and nodular pancreas. Histopathological examination confirmed our diagnosis of diffuse pancreatic adenocarcinoma. This rare presentation of a locally contained and fully resectable diffuse pancreatic adenocarcinoma is being discussed.

Keywords: Diffuse, pancreatic adenocarcinoma, total pancreatectomy.

Correspondence:

Asse Prof Dr Razman Jarmin, Department of Surgery, Universiti Kebangsaan Malaysia Medical Centre, Jalan Yaacob Latif, Bandar Tun Razak 56000 Cheras, Kuala Lumpur, Malaysia.

Tel: +60391456201

Fax: +60391456684.

Email: razman@mail.pukm.ukm.my

Received: Dec 14 2010

Accepted : Jan 4 2011

Introduction

Diffuse pancreatic adenocarcinoma is a rare variation of pancreatic adenocarcinoma representing less than 5% of all pancreatic malignancies. Commonly, a diffusely diseased pancreas would manifest as a metastatic pancreatic carcinoma with its patients presenting in an advanced state of disease where management would solely be palliative. We report a case of diffuse pancreatic adenocarcinoma confined to the pancreas and our management of this patient.

Case Report

A 64-year-old Malay lady presented with a 2 week history of worsening abdominal pain,

jaundice, loss of appetite and progressive weight loss. Her liver profile showed an obstructive picture, while an abdominal ultrasound showed a dilated biliary tree with sludge in the gallbladder. She was then subjected to an endoscopic retrograde cholangiopancreatography (ERCP) which revealed a short segment stricture of the distal common bile duct (CBD) with proximal dilatation and contact bleeding of the ampulla. Although tumour markers revealed a mildly raised CA 19.9, an abdominal CT showed no pancreatic mass or any other suspicious lesion. A repeat ERCP with brush cytology however confirmed presence of malignant cells, thus she was subjected to a Whipple's procedure. Intraoperatively the entire pancreas was hard and nodular although the coeliac axis, porta

hepatitis and other surrounding structures showed no evidence of tumour infiltration. At this point, a differential diagnosis of chronic pancreatitis was entertained. However, frozen sections taken from the body of pancreas confirmed the presence of a malignancy. However, frozen sections of the suprapancreatic lymph nodes, were clear of tumour cells. In view of this, a total pancreatectomy was performed (Fig 1). Histopathological examination of the tumour revealed a moderately differentiated adenocarcinoma diffusely involving the entire pancreas up to 15mm from the tail with no lymphatic infiltration and a clear surgical margin (Fig 2). A follow up review of the patient in the clinic 6 months later revealed no recurrence of symptoms.

Discussion

Diffuse morphology of pancreatic ductal adenocarcinoma is an unusual manifestation that represents only about 5% of all cases of pancreatic adenocarcinoma (1). To date, there is no pathologic definition to describe diffuse pancreatic adenocarcinoma. However, an earlier study defined diffuse disease by the involvement of a tumour of more than 50% along the longitudinal axis of the gland (2). The evolution of diffuse pancreatic adenocarcinoma is still debatable. While some believe that it is a result of rapid progression of an aggressive focal tumour others think that this may simply be attributed to a delayed diagnosis. The third postulation is a synchronous multifocal development of cancer thus exhibiting a diffuse involvement of the gland. Extreme elevations of CA 19-9 levels has been demonstrated in patients with diffuse pancreatic adenocarcinoma (3). This has been postulated as due to the increased tumour burden in a diffusely involved gland as opposed to a focal lesion. However, the marked elevation of this enzyme by itself is inadequate to diagnose diffuse adenocarcinoma

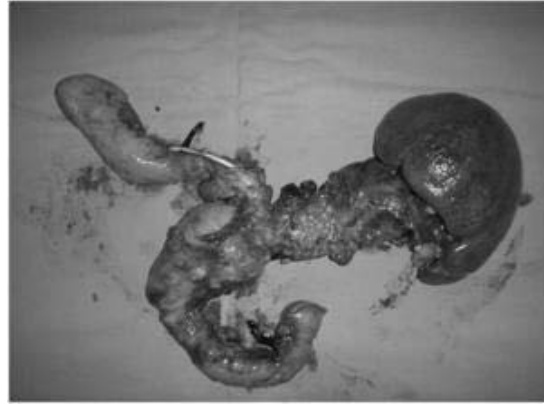

Fig 1: En bloc resection including the spleen, pancreas, duodenum and the gallbladder

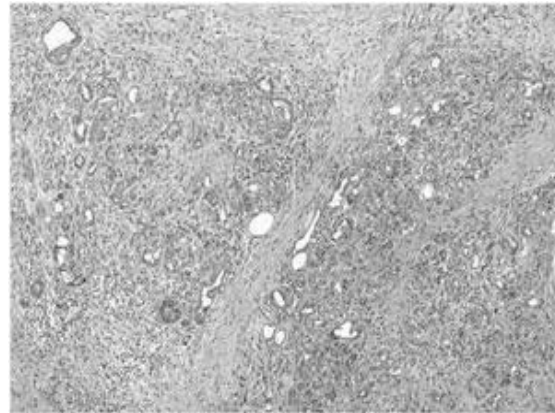


Fig 2: Infiltration of malignant glandular epithelium

as it could also imply an advanced metastatic disease or other differentials such as pancreatic metastasis, lymphoma, and autoimmune or acute pancreatitis.

The histological features of this condition is similar to that of focal lesions, however diffuse pancreatic adenocarcinoma commonly demonstrates all the aggressive characteristics of advanced cancer such as peripancreatic vascular invasion, direct invasion of neighboring structures, peritumoural infiltration, lymphadenopathy and distant metastasis. According to an earlier study on the radiological findings of either a peripheral capsule-like structure, the absence of main pancreatic duct dilatation within the tumour, no parenchymal atrophy and local

invasiveness on computed tomography are believed to be characteristics of diffuse pancreatic adenocarcinoma.

Our patient presented with the usual features of pancreatic cancer, however no clinical or radiological finding exhibited by her was keeping with those of diffuse disease as described above. We were also unable to answer the postulation regarding its evolution. Although only a 15 mm clear margin at the pancreatic tail was observed it remained focally confined to the pancreas which negates an aggressive focal disease or delayed diagnosis which would surely have spread beyond the margins of the pancreas. A multifocal theory was also questionable as our patient did not show an extreme increase in CA 19.9 levels in keeping with an increased tumour burden to the gland. Despite a retrospective review of the CT images, radiological findings that was expected in a diffuse pancreatic adenocarcinoma as described by earlier authors was also not seen in our patient. Finally, despite an extensive literature review no data was available regarding the outcome of diffuse pancreatic

adenocarcinoma after resection when compared to focal disease.

We believe the information regarding characteristics of what is perceived to be diffused pancreatic adenocarcinoma are still rare and an audit on a larger scale is required in order to better understand this condition. A better understanding of this condition would have enabled us to plan better for our operative approach, prepared us for the expectant complications and prime the patient with regards to the effects, complications and outcome of a total pancreatectomy.

References

1. Cubilla AL, Fitzgerald PJ. Pancreatic cancer. I. Duct adenocarcinoma. A clinical pathologic study of 380 patients. *Pathol Annu* 1978;13 Pt 1:241-89.
2. Choi YJ, Byun JH, Kim JY, Kim MH, Jang SJ, Ha HK, Lee MG. Diffuse pancreatic ductal adenocarcinoma: Characteristic imaging features. *Eur J Radiol*. 2008 Aug;67(2):321-8.
3. Rosewicz S, Wiedenmann B. Pancreatic carcinoma. *Lancet*. 1997 Feb 15;349(9050):485-9