

Case Report

An Orbital Solitary Fibrous Tumor: Report of Two Cases with Different Presentation

Hanisah AH¹, Othmaliza O¹, Rona Asnida N¹, Sunder R², Hazlita MI¹(✉)

¹Department of Ophthalmology, Faculty of Medicine, Universiti Kebangsaan Malaysia Medical Centre, Jalan Yaacob Latif, Bandar Tun Razak, 56000 Cheras, Kuala Lumpur, Malaysia.

²Department of Ophthalmology, Kuala Lumpur Hospital, Jalan Pahang, 50586, Wilayah Persekutuan Kuala Lumpur, Malaysia.

Abstract

Solitary fibrous tumour (SFT) is a rare spindle-cell neoplasm that can occur in the orbit. We report two cases of orbital SFT in a 35-year-old female and a 28-year-old male with different presentations. First patient presented with slowly progressive left lateral upper lid mass which is firm in consistency and non tender. Patient had non axial proptosis as the mass compressed the globe inferonasally. There was also funduscopy evidence of choroidal folds superotemporally. There is slight impairment of vision on the left eye comparing to right eye. Meanwhile, the second patient presented with a painless diffuse swelling of left upper eyelid. It was soft in consistency, non fluctuate and no opening or pus discharge noted. There is mild mechanical ptosis, however there was no proptosis and no evidence of compression into the globe nor visual impairment. Computed tomography (CT) imaging revealed a well circumscribed and contrast enhanced soft tissue mass intraorbital extraconal mass in both cases. However in the first case, the tumour was at the level of lacrimal gland with compression of the globe, while in second case, it was superior and posterior to the left lacrimal gland with no globe compression. Both patients underwent complete resection of their tumors. The histological findings showed alternating hypercellular and hypocellular areas composed of bland spindle cells with a fibrous stroma. The strong immunoreactivity for CD34 supported the diagnosis of orbital SFT. There was no recurrence at the 2nd and 3rd year follow-up visits for both patients. SFT should be considered as one of the differential diagnosis of an orbital tumor. The combination of CT scan, histologic findings and immunohistochemical staining provide accurate diagnosis. En bloc excision of the tumour is the mainstay of treatment.

Keywords: CD 34, orbit, orbital tumor, solitary fibrous tumour, vimentin

Correspondence:

Hazlita Mohd Isa, Department of Ophthalmology, Faculty of Medicine, Universiti Kebangsaan Malaysia Medical Centre, Jalan Yaacob Latif, Bandar Tun Razak, 56000 Cheras, Kuala Lumpur, Malaysia. Tel: +603-9145 5981 Fax: +603-9145 6673 Email: rhdmi@yahoo.co.uk

Date of submission: 13 Apr, 2016

Date of acceptance: 4 Aug, 2016

Introduction

Solitary fibrous tumour (SFT) is a rare, benign mesenchymal tumour. It is a slow progressing spindle cell tumour that commonly affects the pleura (1). SFT however may also arise extrapleurally such as in the upper airway tract, nasal, paranasal sinuses, parotid gland, salivary glands, thyroid, lung, mediastinum, pericardium, peritoneum, liver, spine, soft tissue, and

also the orbit (2). We report two cases of orbital solitary fibrous tumour in our centre.

Case Report

Case 1

A 35-year-old Malay female with no underlying medical illness, presented to our centre with a six

months history of painless swelling of the left upper eyelid. She denied any blurring of vision, diplopia, redness of the eyes, discharge, headache, nausea or vomiting. There was no associated constitutional symptom, hyper- or hypothyroid symptoms. She denied any other masses or lumps on her body. Other systemic, medical, surgical, family and drug histories were unremarkable.

On ocular examination, her visual acuity on the right was 6/6 and her left visual acuity was 6/9. She was found to have a left 4mm non axial proptosis. There was a firm non tender mass palpable at the left lateral upper lid (Fig. 1). Her globe was displaced inferonasally. Her extra ocular movements appeared full in both eyes and she denied any diplopia. Anterior segment examination and intraocular pressures of both eyes were normal. On funduscopy, the left posterior segment showed evidence of choroidal folds superotemporally. However, her left optic disc and macula was found to be normal. Her right fundus was unremarkable. Complete systemic examination revealed no abnormalities such as organomegaly or lymphadenopathies. Patient also had no signs of hypo or hyperthyroidism.

All blood investigations which included full blood count and picture, renal profile, liver function test, erythrocyte sedimentation rate (ESR) and thyroid function test were normal. CT scan of the brain and orbit was performed which showed a left extraconal mass superotemporally, at the level of the left lacrimal gland (Fig 2). The mass was noted to be pressing on the globe. A total excision of the tumour was performed via lateral orbitotomy. The mass was noted to be 2.5 x 2.7 x 1.7cm in measurement, grayish in colour and well vascularised. On histopathology, the mass showed areas of both hyper and hypocellular regions. There were evidence of patternless proliferation of spindle shaped cells and abundance of collagen tissue with minimal pleomorphism (Fig 3). There was no evidence of necrosis or mitotic activity seen. There was also no evidence of glandular elements. Further immunohistochemical staining on the specimen performed showed positivity for CD34 and vimentin.

Case 2

A 28-year-old male, no underlying medical illness presented with left eye upper lid swelling which gradually increased in size within 5 months. It was not associated with pain, double vision or proptosis of the eye. There was no previous trauma. There was no family history of malignancy.

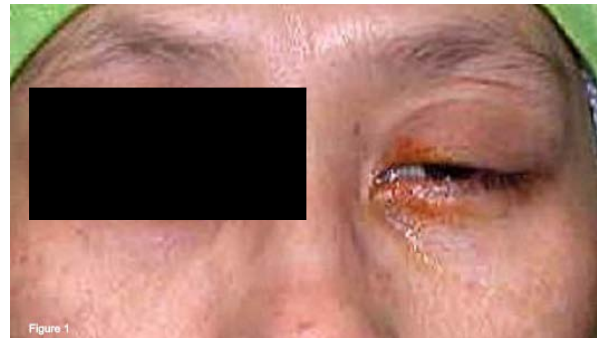

Figure 1: Firm, non-tender palpable mass at the left upper lid

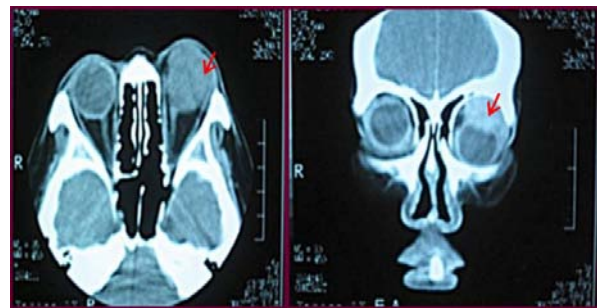


Figure 2: Axial and coronal view of the CT scan orbit shows superotemporal extraconal orbital mass (arrow)

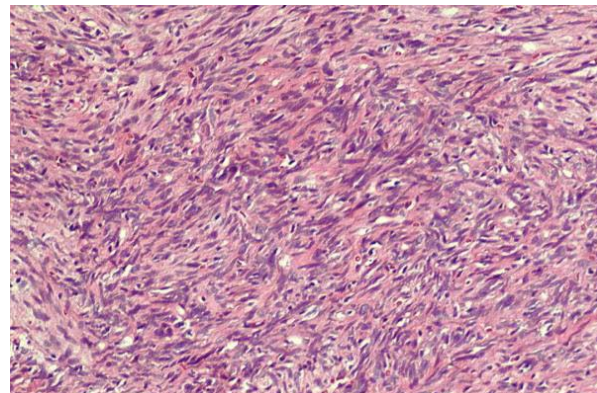


Figure 3: Histopathology showing areas of hyper and hypocellular regions with patternless proliferation of spindle shaped cells

On examination, bilateral visual acuity was 6/6. There was a diffuse swelling of left upper eyelid. It was soft in consistency, non fluctuate and no opening or pus discharge noted. The swelling causes a mild mechanical ptosis of the left upper eyelid (Fig. 4). Anterior and posterior segment examinations in both eyes were unremarkable. Exophthalmometry did not reveal any proptosis. Binocular single vision testing showed diplopia in up gaze. Hess chart showed normal extra ocular movements. Systemic examinations of the patient were normal.

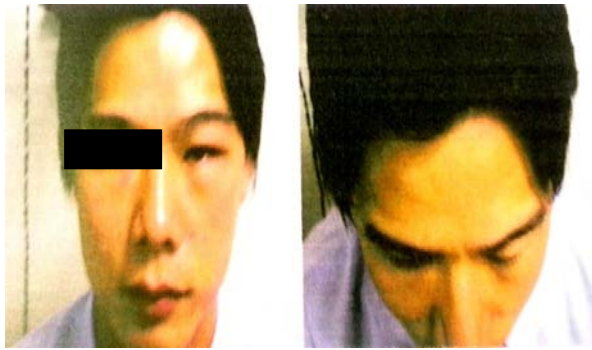

Figure 4: Swelling of the left upper lid with mechanical ptosis

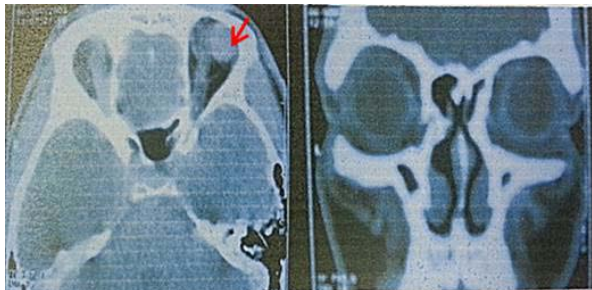


Figure 5: CT scan orbit shows intraorbital extraconal orbital mass (arrow)

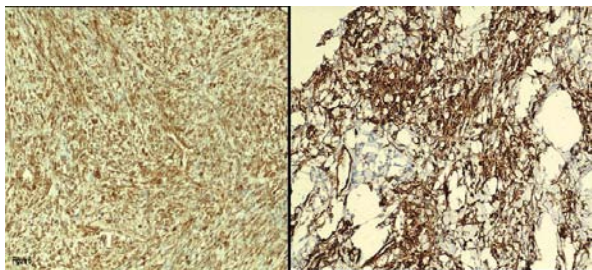


Figure 6: Immunohistochemical staining on the specimen performed showed positivity for CD34 (right) and Vimentin (left)

Complete blood investigations (including full blood count, blood sugar, renal profile, liver function and ESR) were all normal. CT scan of orbit and brain showed an intraorbital extraconal mass (Fig. 5), appearing similar to a muscle density situated superiorly behind the left lacrimal gland.

An excision biopsy was performed and the excised mass measured 2.0 x 1.4 x 1.0 cm. It was firm and yellowish in colour. Histopathology analysis revealed a lesion composed of spindle shaped cells within collagen bundles and vascular channels. There were no mitotic figures or any lacrimal gland element found. Immunostaining was positive for vimentin and CD34 (Fig. 6) and negative for S100 and Factor 8 antigen indicating the diagnosis of orbital solitary fibrous tumor.

Discussion

Solitary fibrous tumor (SFT) was first described by Klemper and Rabin in 1931 and also known as localized tumor of the pleura as it was believed to be derived from mesothelium (1). However, 63 years later, in 1994, Dorfman et al. described the first orbital solitary fibrous tumour (3). Presently, with new advances in medical research all over the world, more cases of orbital solitary fibrous tumour are being diagnosed and reported.

Clinically, patients with orbital solitary fibrous tumour present with a painless unilateral proptosis. The mass progresses slowly, taking months to years before there are any clinical manifestations. Vision, intraocular pressure and extra ocular movements are usually preserved. There is no age or sexual predilection noted (4). These presentations were manifested in both of the cases above. However in the case of many intraorbital tumours, signs and symptoms alone are not sufficient to give an exact diagnosis.

On radiological imaging, solitary fibrous tumor usually presented as isolated soft tissue masses with a smooth, well-circumscribed surface. There is no bony destruction in solitary fibrous tumor. However, there is remodelling of the bone due to pressure effect by the tumor (5). These radiological findings are similar in both of our cases whereby patient had isolated well circumscribed lesion without bone destruction.

Optic nerve and globe compression are uncommon findings in the case of solitary fibrous tumor. Thus, vision and ocular motility are usually preserved (6). However, this may not be true for all cases as portrayed in the first patient. The mass was seen compressing the globe resulting in choroidal folds which may have led to the slight visual disturbance in her left eye whereby her visual acuity (6/9) compared to her right visual acuity (6/6).

Radiologically, CT scan usually will show a well-defined soft tissue mass with heterogeneously or homogeneously strong enhancement (4). On magnetic resonance imaging (MRI), a solitary fibrous tumour will be isointense to grey matter in T1 and hypointense to grey matter in T2. It will show homogenous enhancement on gadolinium contrast. The mass also frequently demonstrate central foci that are profoundly hypointense on both T1 and T2 (6). In both the cases, CT scan were done and showed a well-defined soft tissue mass with homogeneously enhancement with contrast.

The diagnosis of SFT relies heavily on the histological features and immunohistochemical confirmation. Classical feature of SFT is the presence of spindle cells that grow in a haphazard fashion in a variably cellular stroma, known as the “patternless pattern”. The stroma is often heavily collagenized, with bands of collagen interspersed between the tumor cells. Branching staghorn vascular channels is a prominent feature, similar to the vascular spaces seen in haemangiopericytoma (7). This similarity makes it difficult to determine the exact diagnosis and thus immunohistochemical staining play an important role for the confirmation of SFT.

SFT usually shows a strong and diffuse immunoreactivity to vimentin, CD34 and bcl-2 while other muscular markers, cytokeratins, S-100 and factor VIII are often negative. A uniform positivity for vimentin and CD34 supports the diagnosis of solitary fibrous tumour. The tumour is strongly reactive (79-100%) to CD34 antigen (8). As seen in both of the cases, the diagnosis of orbital solitary fibrous tumour was made primarily from the immunohistochemical findings of the mass excised, which was positively reactive to both CD34 and vimentin.

Generally orbital solitary fibrous tumours pursue a benign non aggressive course and can be cured with complete excision (9). Nevertheless, malignant form of orbital SFT has been reported (10). In addition local recurrences may occur after excision thus long term follow up post excision is essential (11).

Conclusion

Orbital SFT is rare but should be considered as one of the different diagnosis when dealing with an orbital mass. Histology features and immunohistochemical staining with vimentin and CD34 is helpful in making diagnosis of this orbital tumour and should be used whenever possible. Orbital SFT is generally non aggressive and treated by performing complete excision of the mass. Despite this, continuous follow up of the patient is beneficial as local recurrences have been known to occur.

References

1. Havlik DM, Farnath DA, Bocklage T. Solitary fibrous tumor of the orbit with a t(9;22)(q31;p13). Arch Pathol Lab Med 2000;124(5): 756–8.

2. Cheang WM, Wei LC, Wang J, Tsai HY. Orbital solitary fibrous tumor: A report of two cases. Taiwan J Ophthalmol 2013; 3(3): 120-2.
3. Dorfman DM, To K, Dickersin GR, Rosenberg AE, Pilch BZ. Solitary fibrous tumor of the orbit. Am J Surg Pathol 1994;18(3): 281-7.
4. Kim HJ, Kim H-J, Kim YD, et al. Solitary fibrous tumor of the orbit: CT and MR imaging findings. AJNR Am J Neuroradiol 2008; 29(5): 857–62.
5. Gigantelli JW, Kincaid MC, Soparkar CN, et al. Orbital solitary fibrous tumor: radiographic and histopathologic correlations. Ophthal Plast Reconstr Surg 2001; 17(3): 207-14.
6. Krishnakumar S, Subramanian N, Mohan ER, Mahesh L, Biswas J, Rao AN. Solitary fibrous tumour of the orbit: a clinicopathologic study of six cases with review of the Literature. Surv Ophthalmol 2003; 48(5): 544-54.
7. Hsu SS, Lai PH, Wang JS, Yip CM. Solitary fibrous tumor of the orbit. J Chin Med Assoc 2004; 67(9): 483-6.
8. Tam ES, Chen EC, Nijhawan N, Harvey JT, Howarth D, Oestreicher JH. Solitary fibrous tumor of the orbit: a case series. Orbit 2008; 27(6): 426-31.
9. Kim HY, Lee SY, Kang SJ, Kim HJ. Solitary fibrous tumor of the orbit: a poorly-recognized orbital lesion. Acta Ophthalmol Scand 1999; 77(6): 704-8.
10. Girnita L, Sahlin S, Orrego A, Seregard S. Malignant solitary fibrous tumour of the orbit. Acta Ophthalmol 2009; 87(4): 464–7.
11. Alexandrakis G, Johnson TE. Recurrent orbital solitary fibrous tumour in a 14 year old girl. Am J Ophthalmol 2000; 130(3): 373-6.